NEURORRADIOLOGIA

Cristina Moura
Neurorradiologia, HUC – CHUC

NEURORRADIOLOGIA

Diagnóstico

Intervenção **Vascular**

Não vascular

CRANIO e FACE

COLUNA VERTEBRAL

TÉCNICAS

Radiologia clássica

Tomografia Computorizada (TC)

Ressonância Magnética Nuclear (RM)

Angiografia (ASD)

RADIOLOGIA CLÁSSICA

RADIOGRAFIA SIMPLES

- ↘ Fácil acesso
- ↘ Estudo morfológico
- ↘ Estudo dinâmico

mas

- ↙ Falta de resolução para os tecidos moles

L
Waters

L
Caldwell

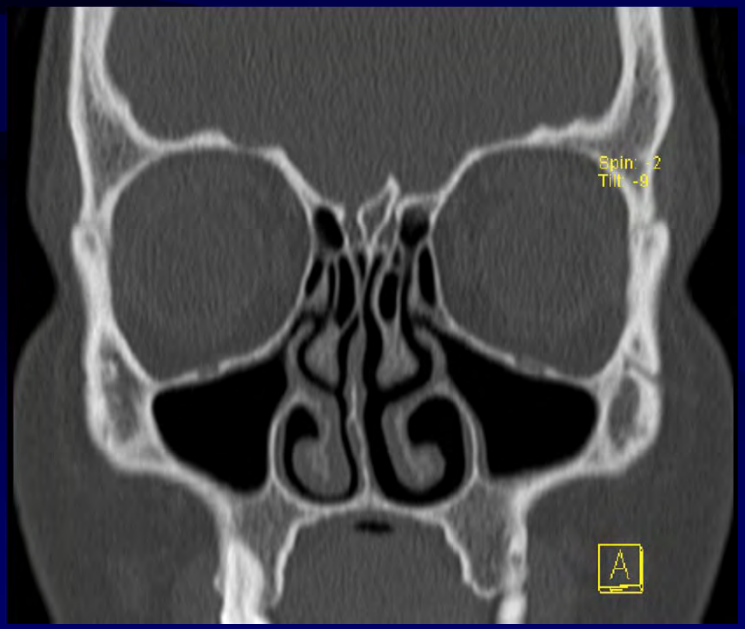
Spin -2
Tilt -9
A

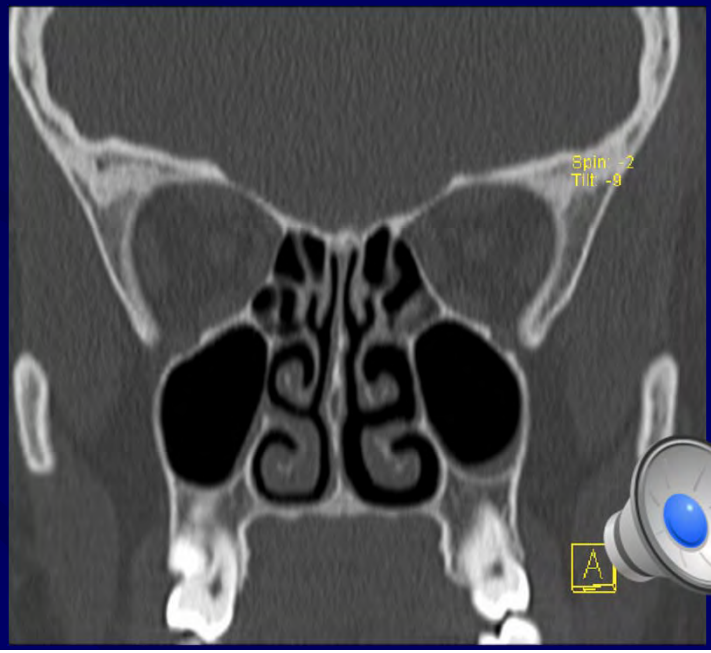
Spin -2
Tilt -9
A

RADIOGRAFIA SIMPLES

Indicações

- Primeira aproximação ao diagnóstico topográfico das lesões traumáticas
- Estudo das curvaturas e da biomecânica

Cervicobraquialgia esquerda

RMN

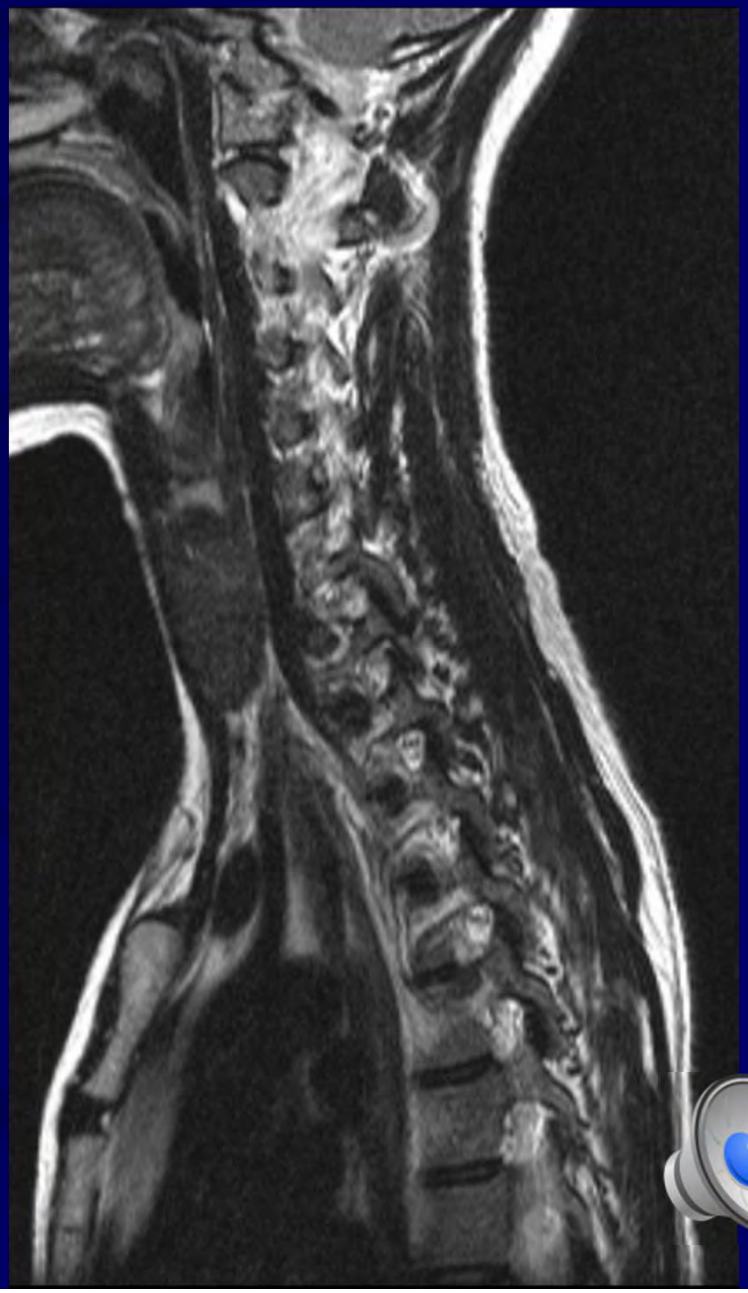

RX - estudo dinâmico

TOMOGRAFIA COMPUTORIZADA

- Não invasivo
- Largamente disponível e acessível
- Contraste osso / tecidos moles
- Aquisição volumétrica
  reconst. MPR e 3D

RESSONÂNCIA MAGNÉTICA

- Não ionizante
- Não invasivo
- Liberdade de planos de estudo
- Grande detalhe morfológico e de sinal
- Elevado contraste e resolução espacial
- Grande sensibilidade ⇒ detecção precoce

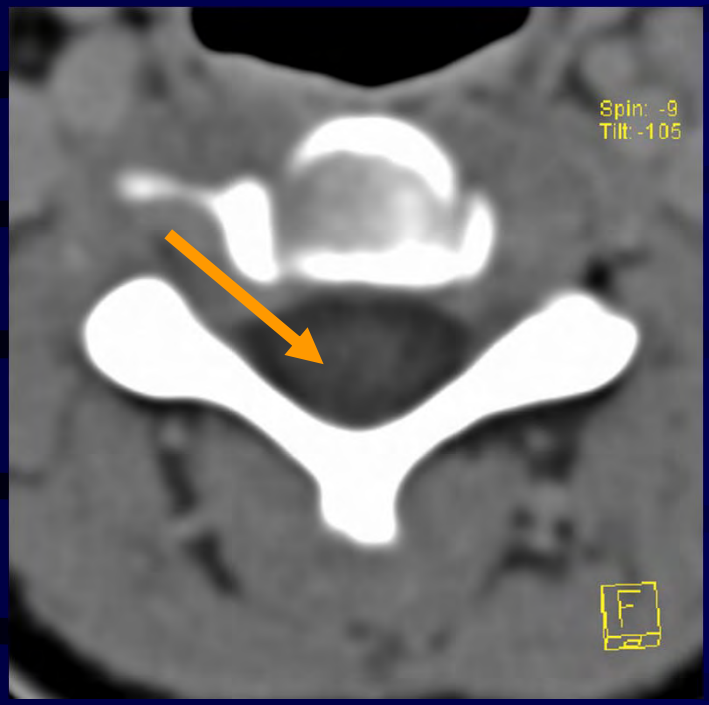
Spin: -9
Tilt: -105

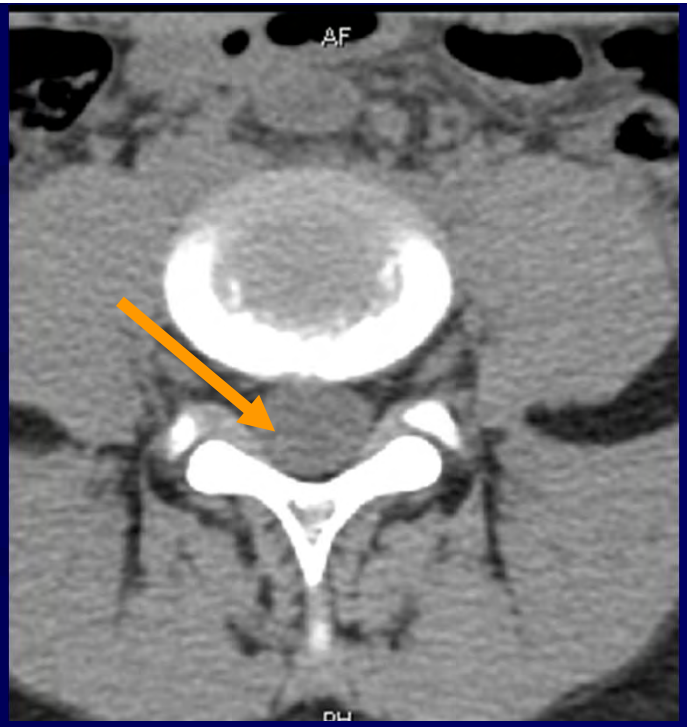
AF

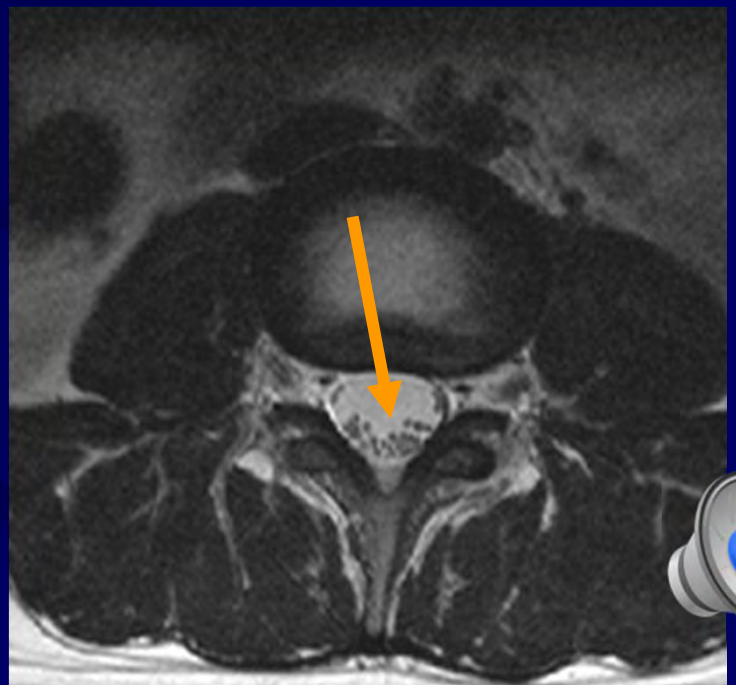

RESSONÂNCIA MAGNÉTICA

Limitações

- Acesso pouco fácil
- Claustrofobia
- Doentes pouco colaborantes
- Presença de material ferromagnético

ASD

- Invasivo
- Complementar da Angio-TC e Angio-RM
  - aneurismas
  - MAVs
  - patologia dos pequenos vasos
- Intervenção

TC CRANIO

Aquisição: sequencial ou espiral
Contraste iodado iv

Reconstruções: MPR, 3D

Angio-TC

TC-Perfusão

P 265

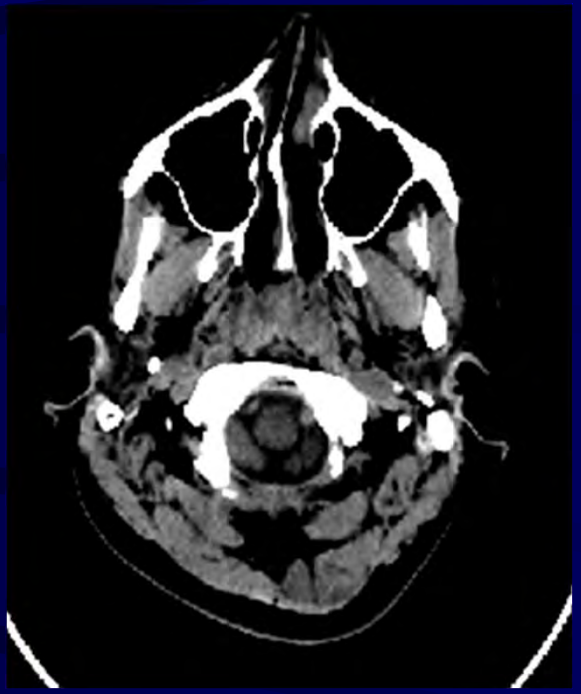

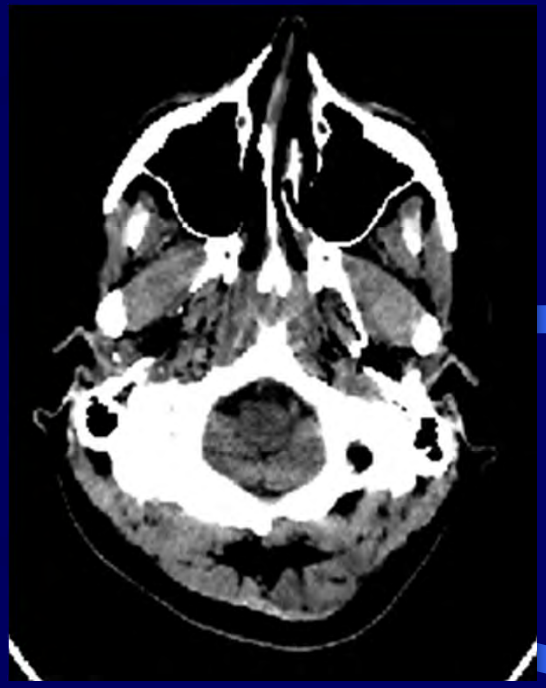

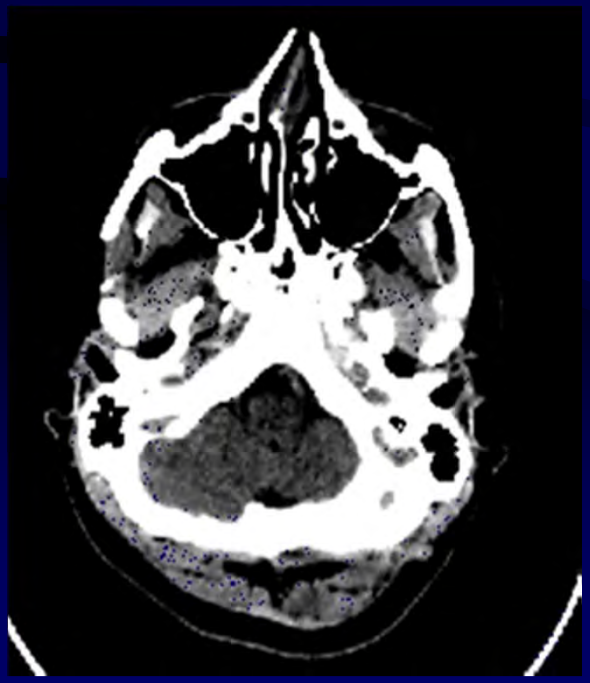

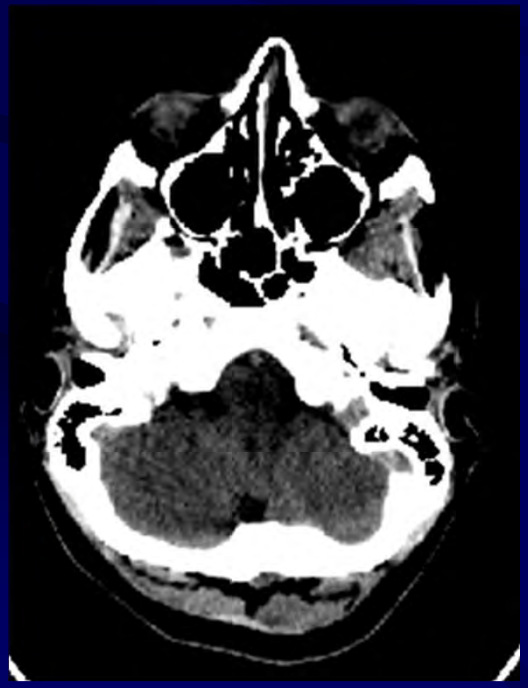

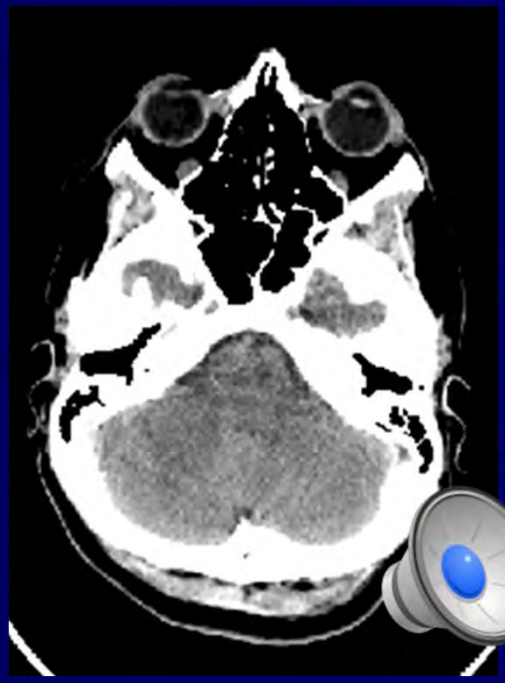

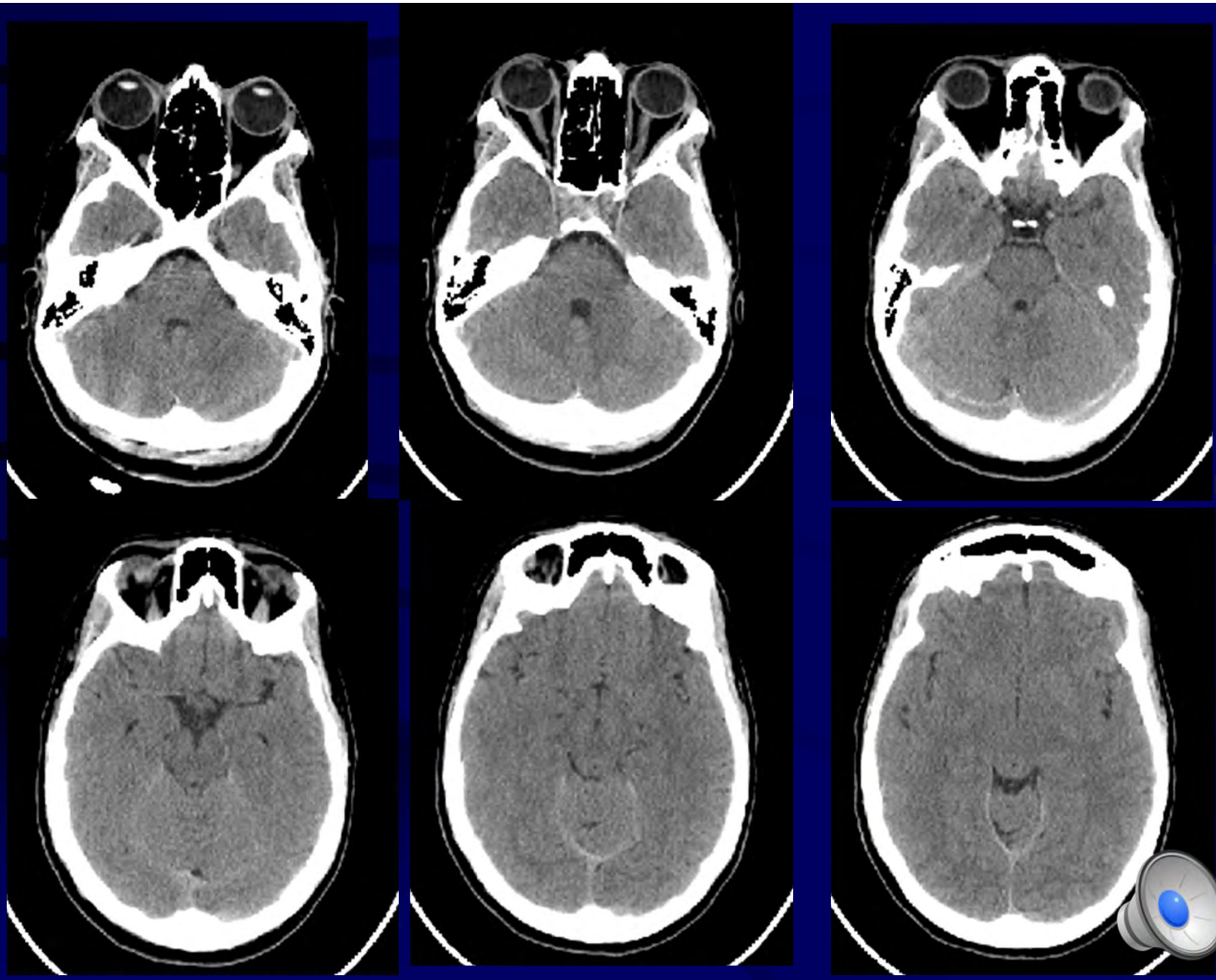

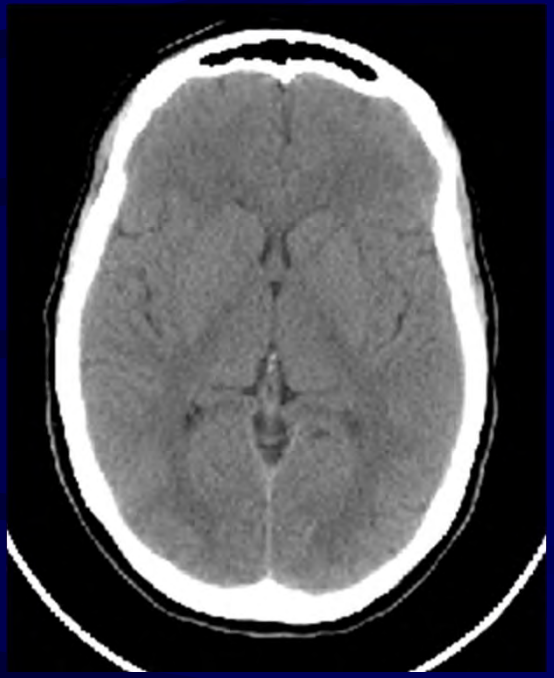

RM CRANIO

Sequências utilizadas: T1, DP/T2, FLAIR….
3D

Planos: sagital, transversal, coronal…

Sequências especiais: Angio, Difusão , Perfusão,
Espectroscopia, Funcional…

Contraste paramagnético iv

T1

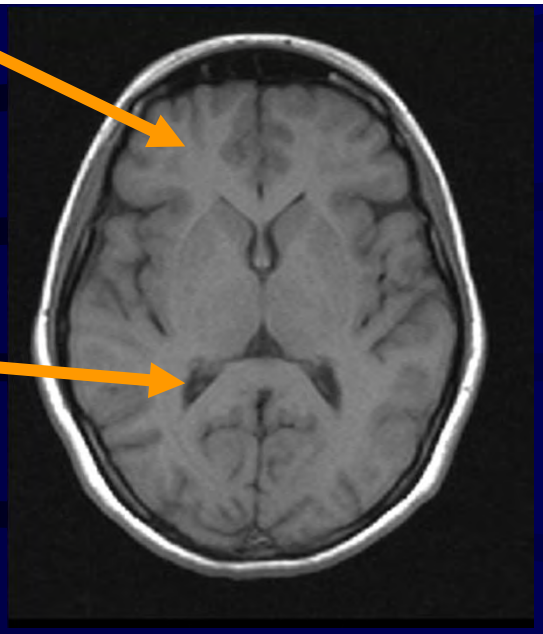

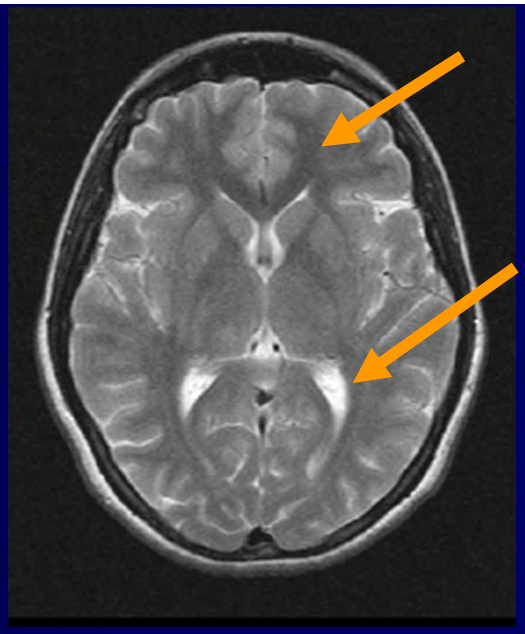

T2

FLAIR

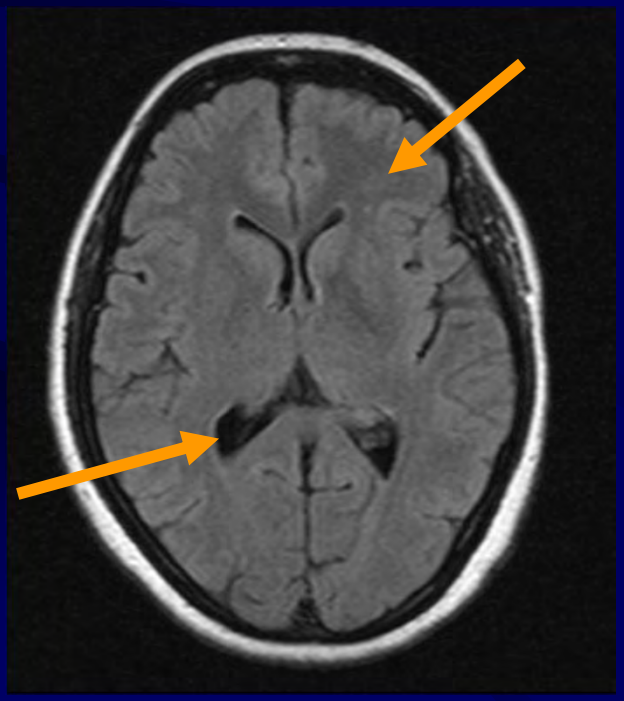

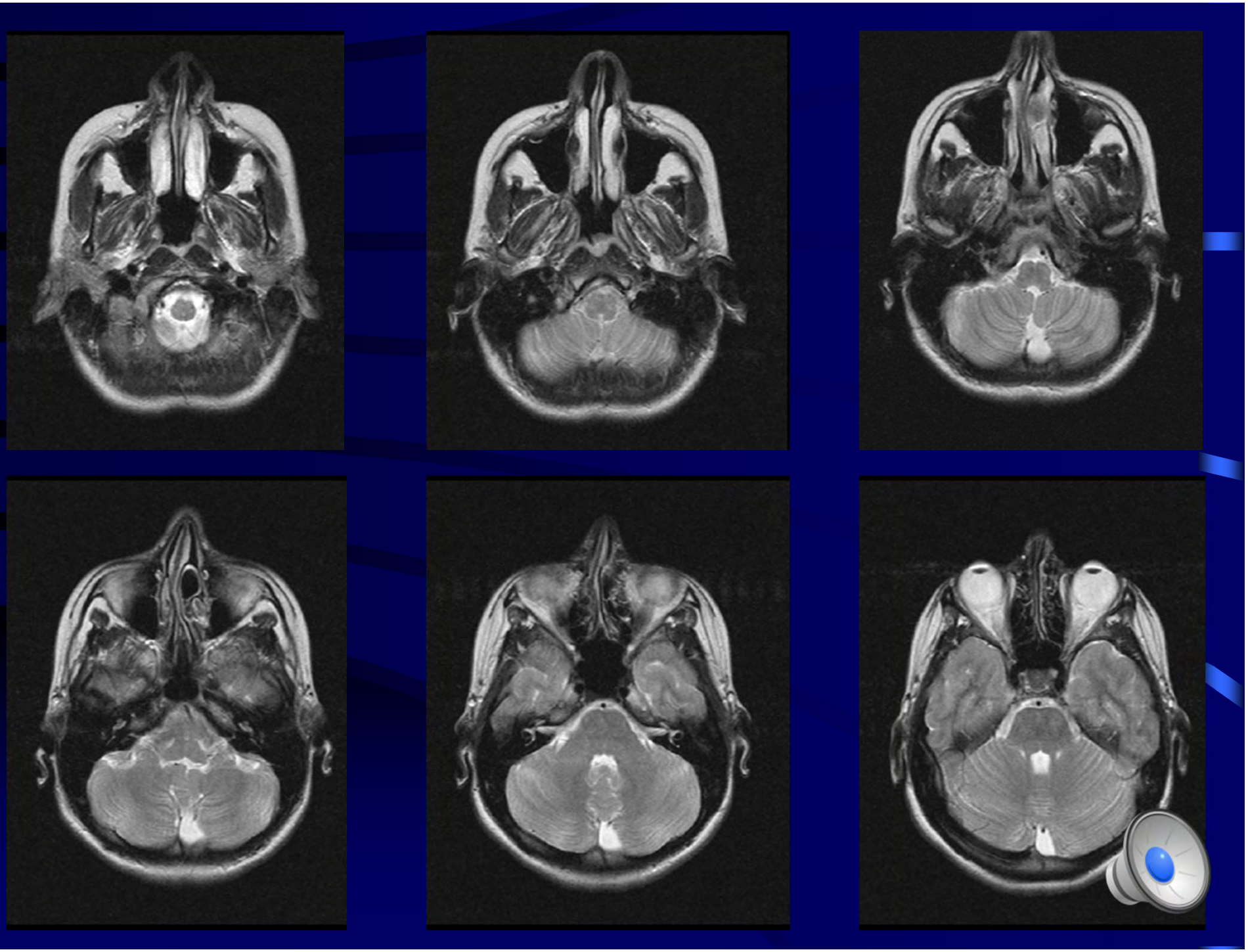

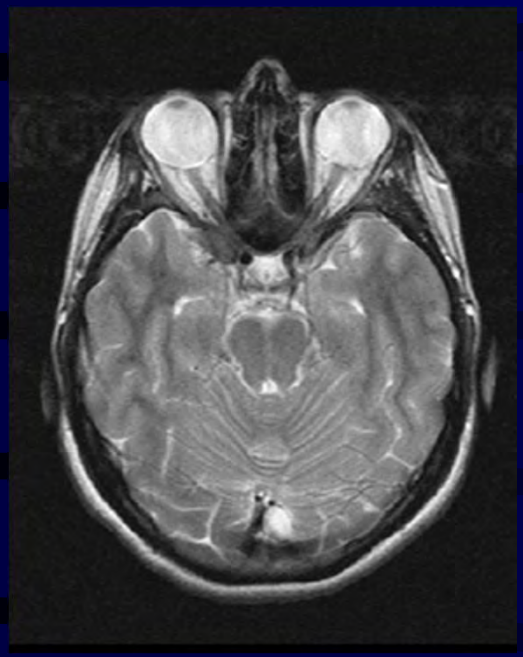
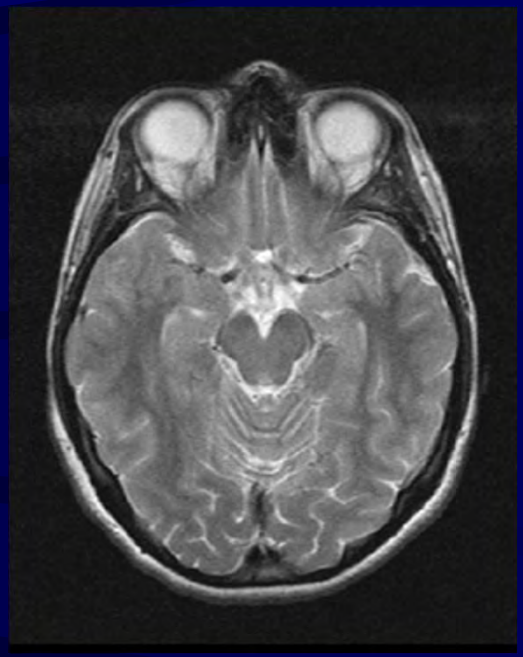
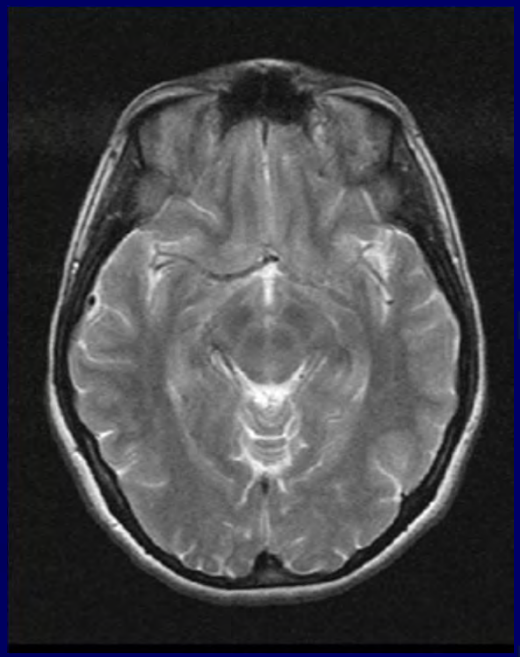
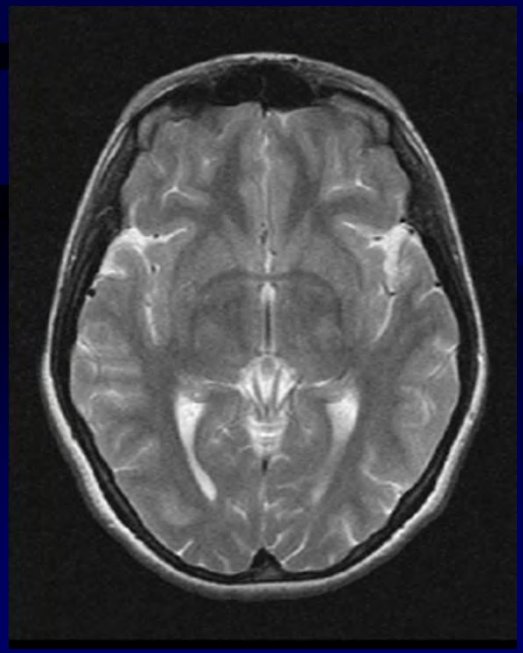
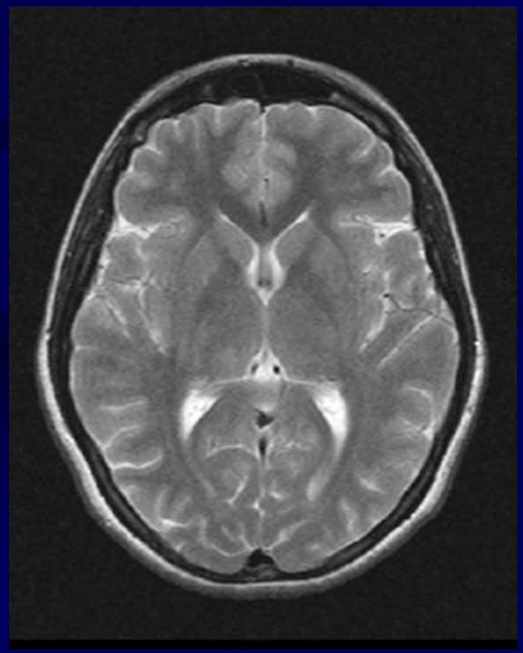
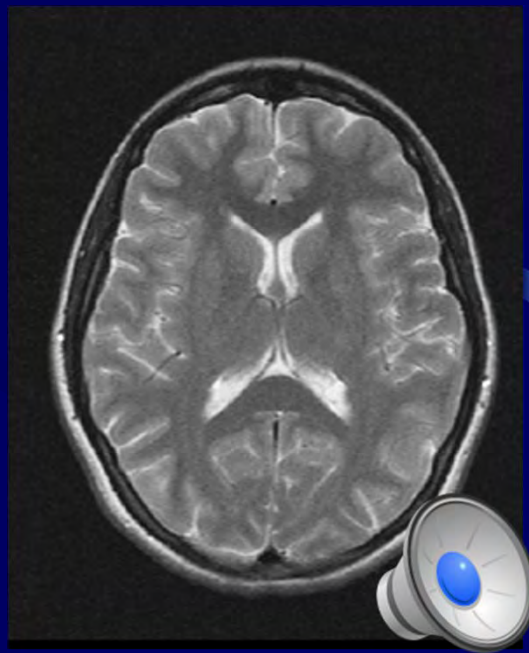

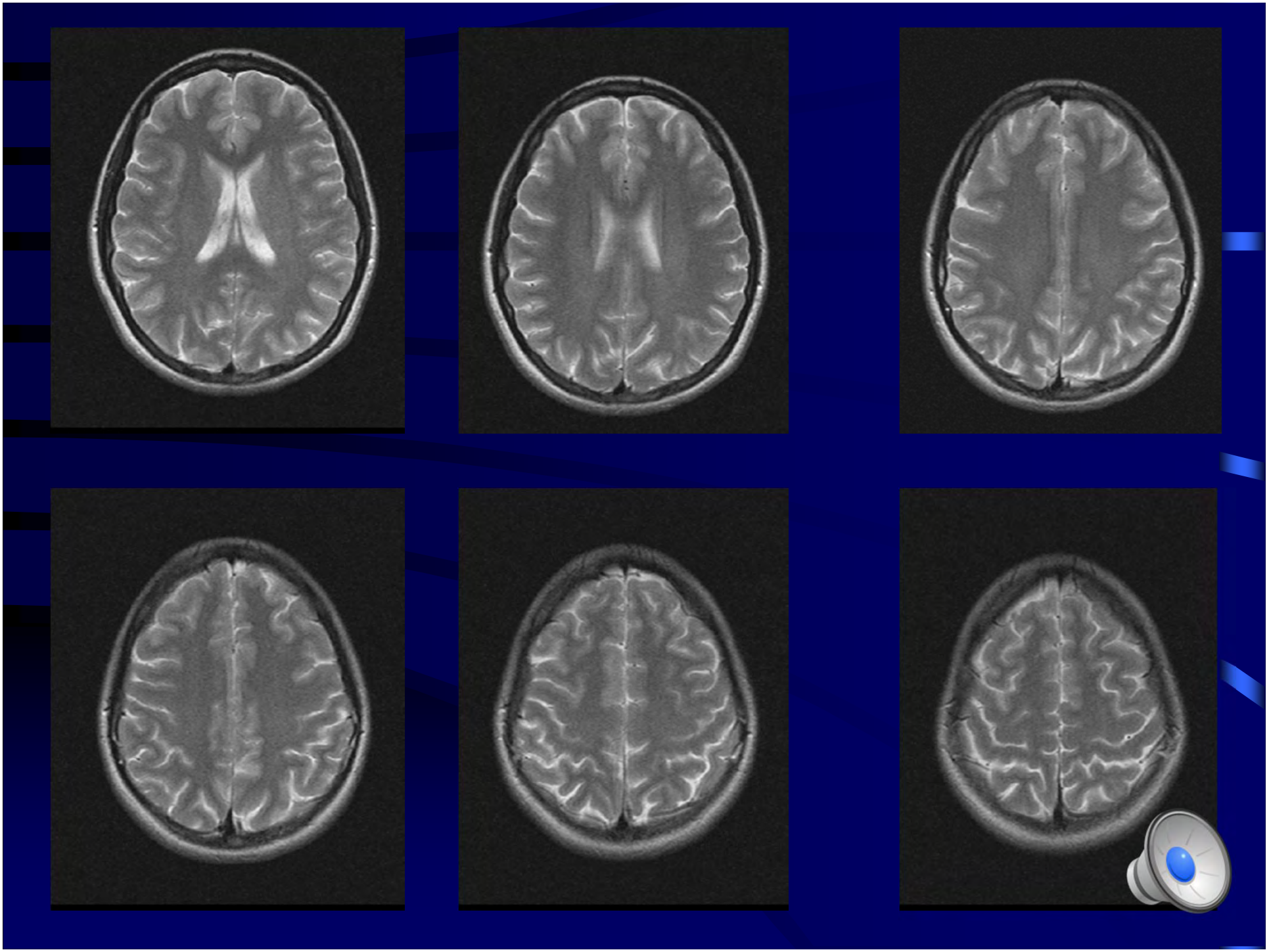

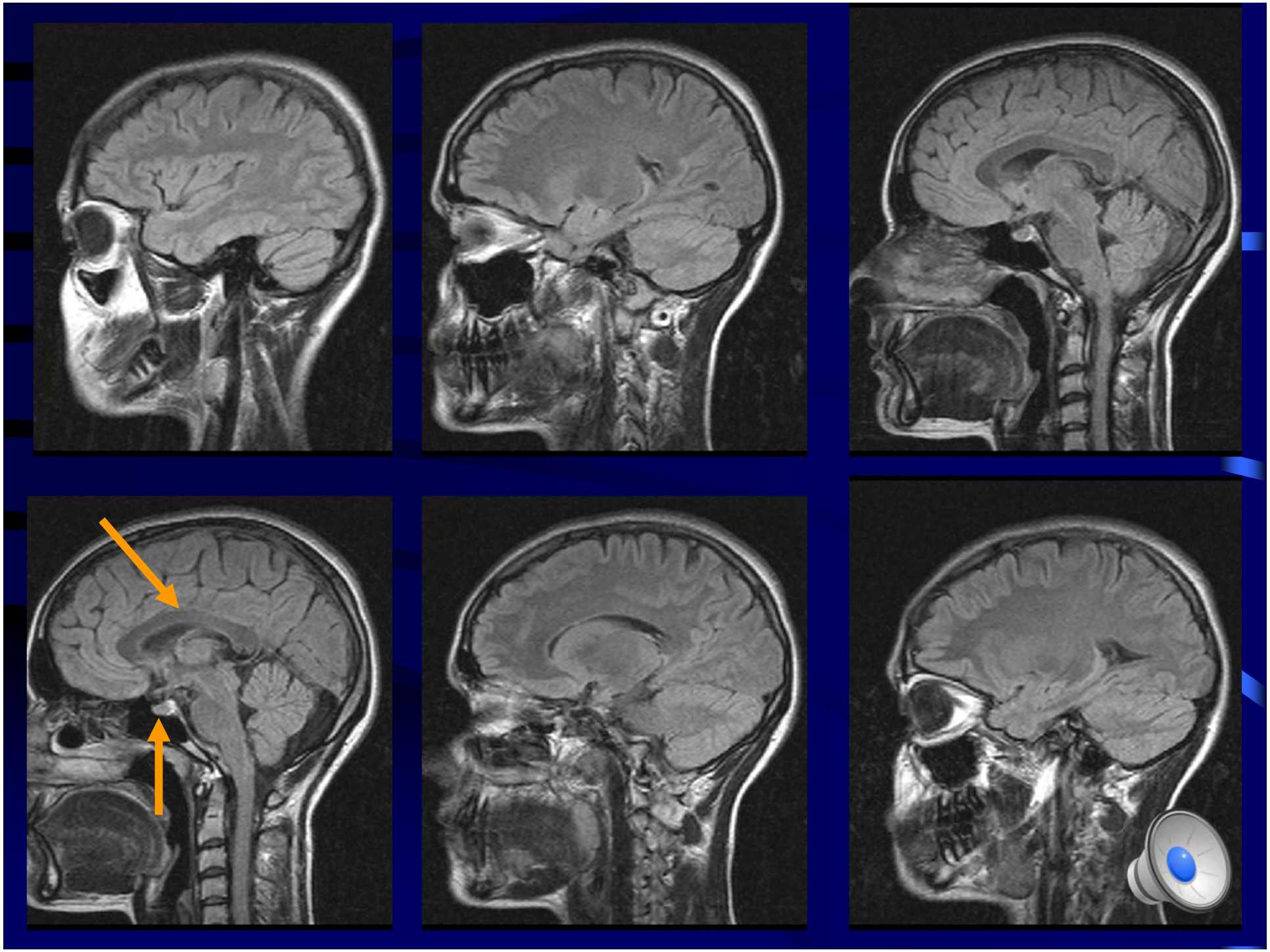

Brain
Sagittal T1

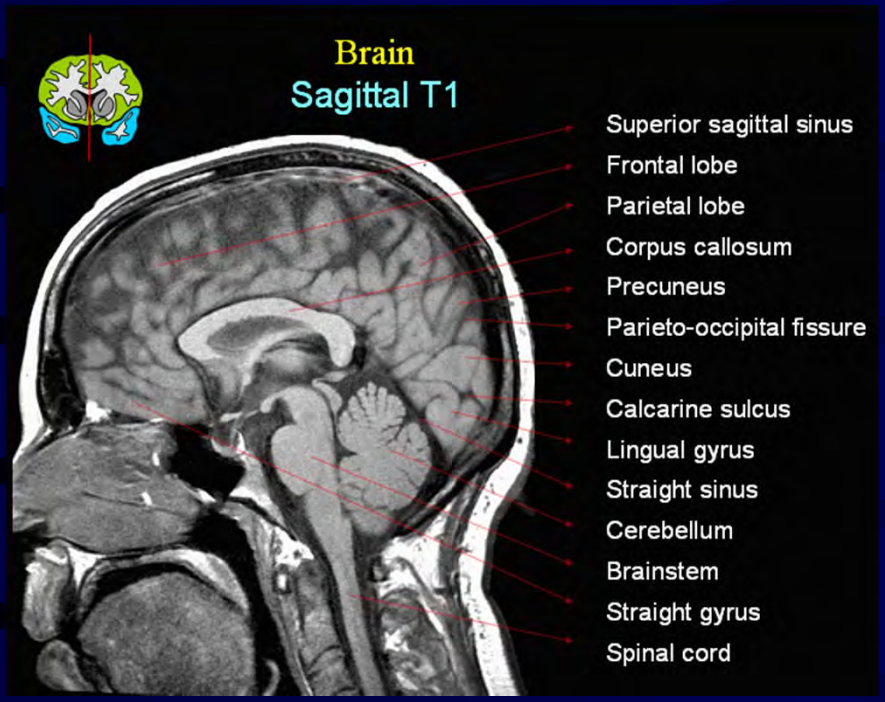

- Superior sagittal sinus
- Frontal lobe
- Parietal lobe
- Corpus callosum
- Precuneus
- Parieto-occipital fissure
- Cuneus
- Calcarine sulcus
- Lingual gyrus
- Straight sinus
- Cerebellum
- Brainstem
- Straight gyrus
- Spinal cord

Brain
Axial T2

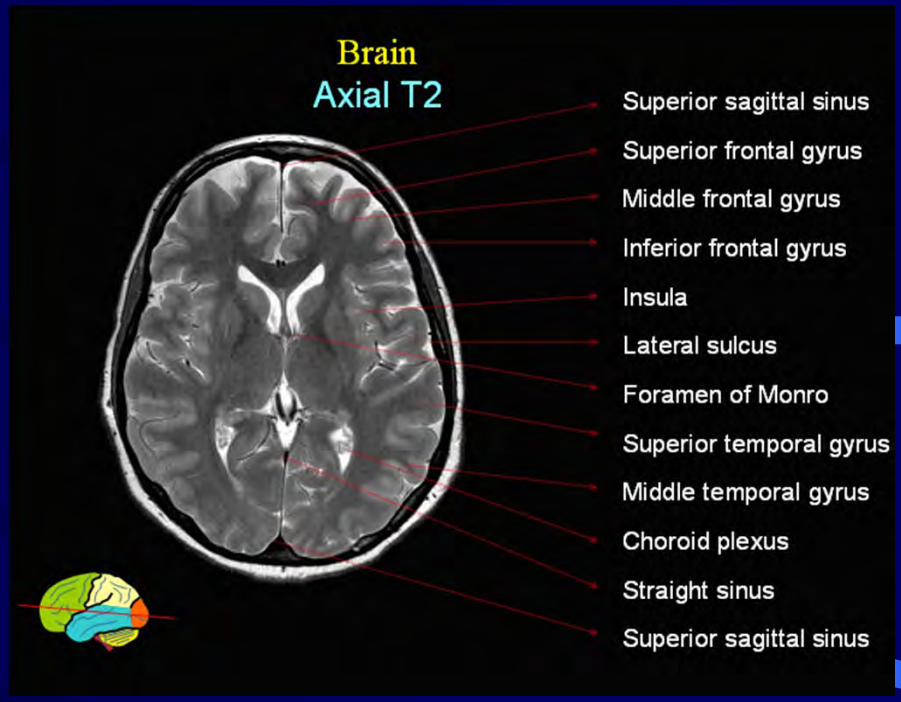

- Superior sagittal sinus
- Superior frontal gyrus
- Middle frontal gyrus
- Inferior frontal gyrus
- Insula
- Lateral sulcus
- Foramen of Monro
- Superior temporal gyrus
- Middle temporal gyrus
- Choroid plexus
- Straight sinus
- Superior sagittal sinus

Brain
Coronal T2

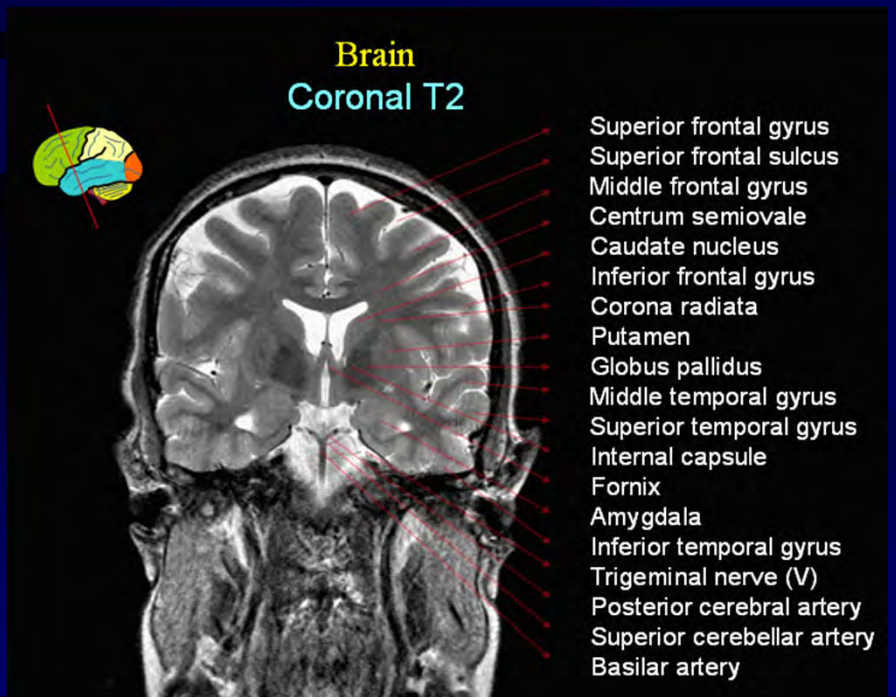

- Superior frontal gyrus
- Superior frontal sulcus
- Middle frontal gyrus
- Centrum semiovale
- Caudate nucleus
- Inferior frontal gyrus
- Corona radiata
- Putamen
- Globus pallidus
- Middle temporal gyrus
- Superior temporal gyrus
- Internal capsule
- Fornix
- Amygdala
- Inferior temporal gyrus
- Trigeminal nerve (V)
- Posterior cerebral artery
- Superior cerebellar artery
- Basilar artery

Brain
Coronal T2

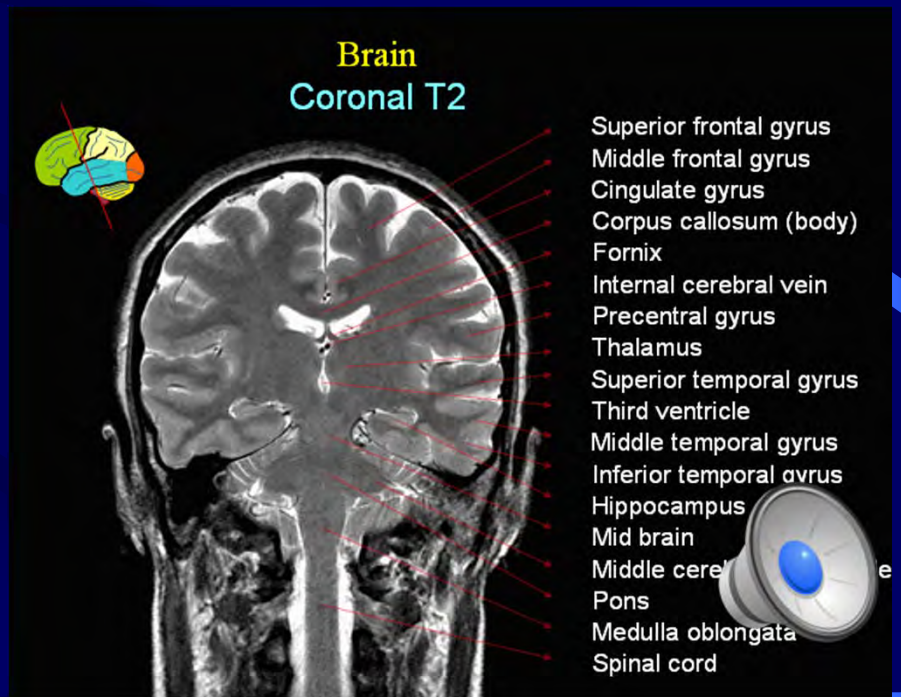

- Superior frontal gyrus
- Middle frontal gyrus
- Cingulate gyrus
- Corpus callosum (body)
- Fornix
- Internal cerebral vein
- Precentral gyrus
- Thalamus
- Superior temporal gyrus
- Third ventricle
- Middle temporal gyrus
- Inferior temporal gyrus
- Hippocampus
- Mid brain
- Middle cere[illegible]e
- Pons
- Medulla oblongata
- Spinal cord

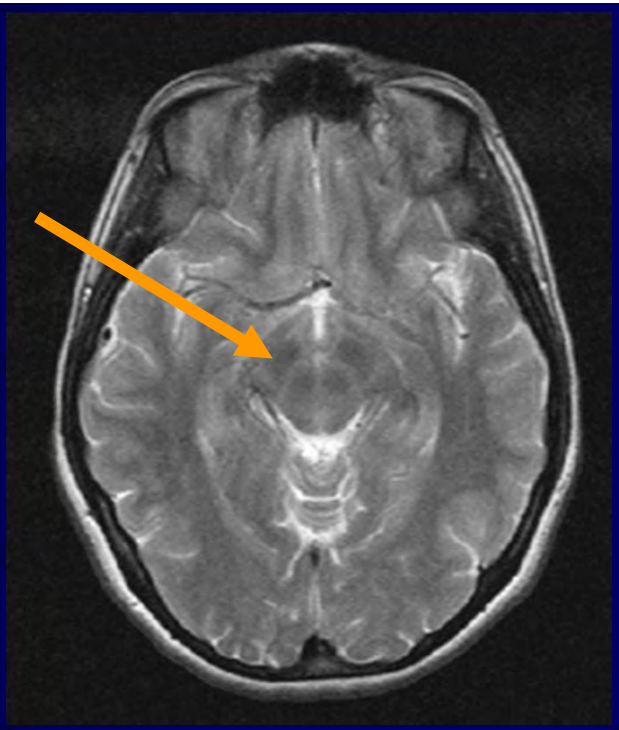

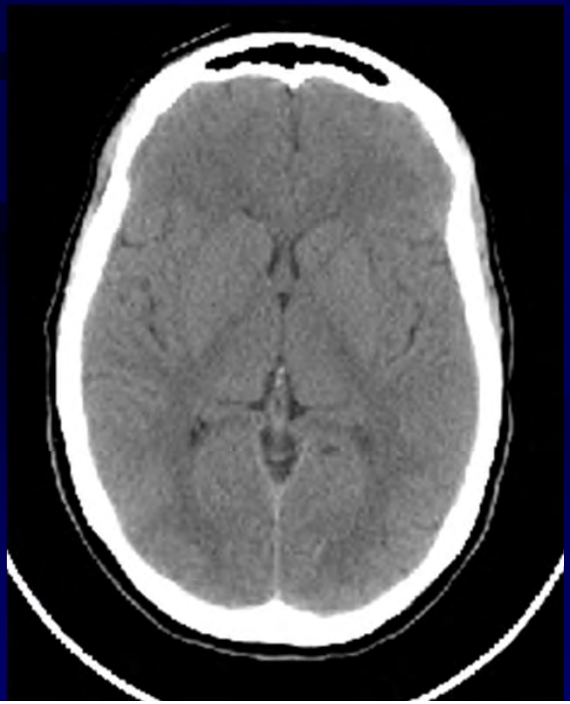

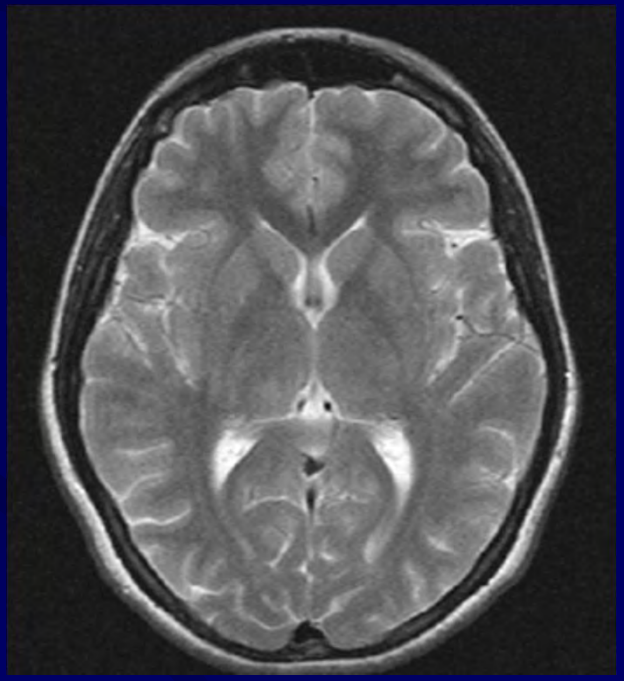

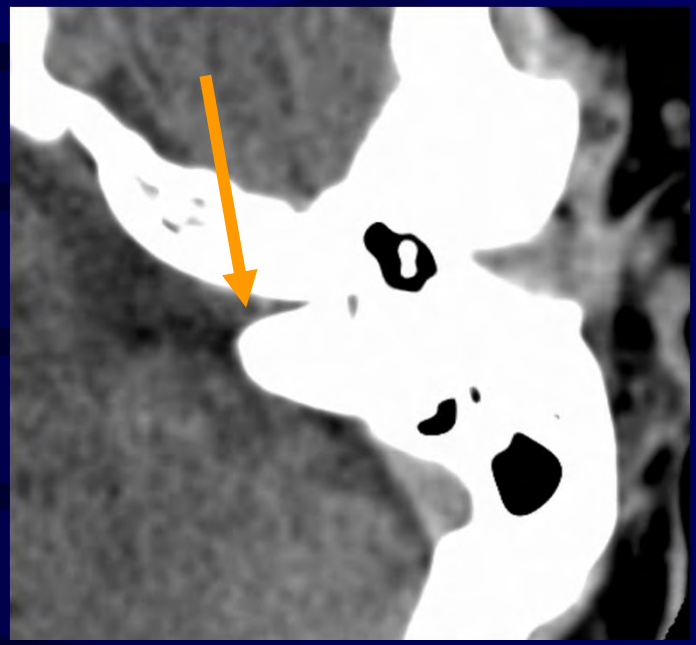

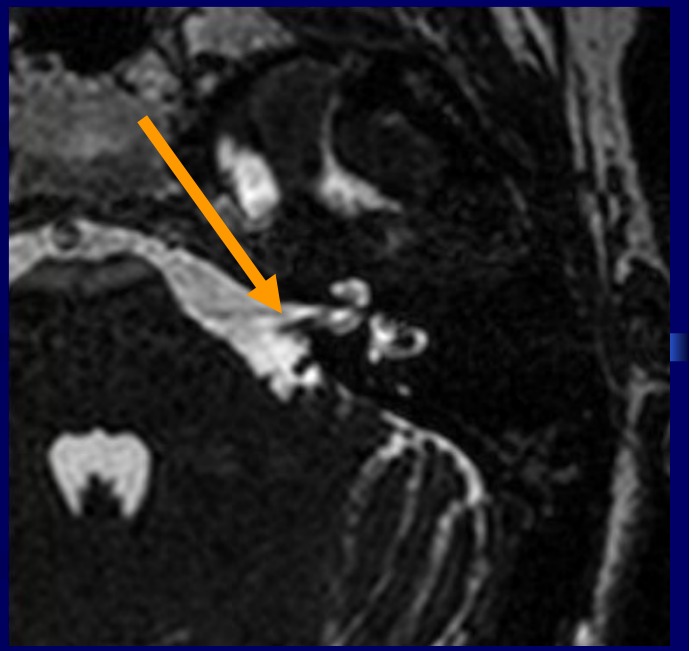

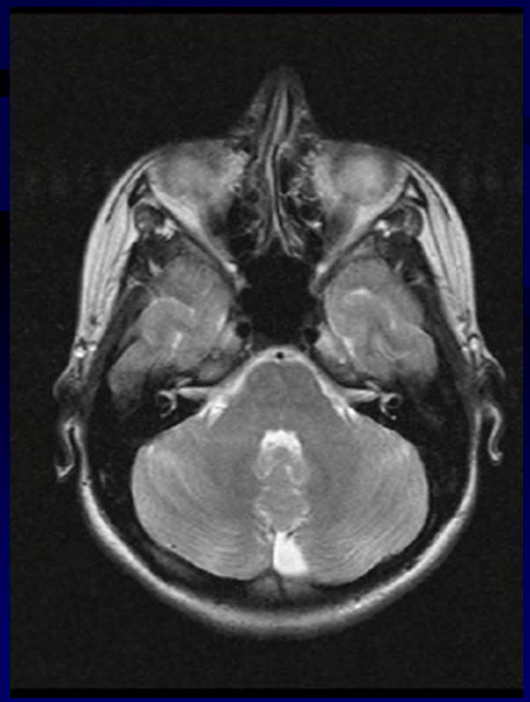

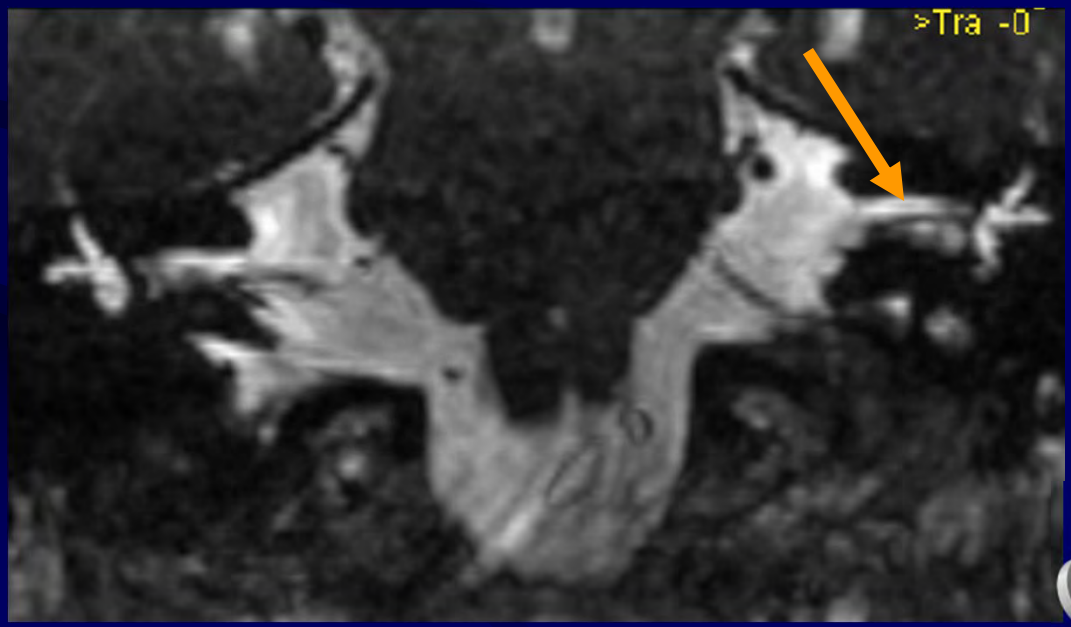
>Tra -0

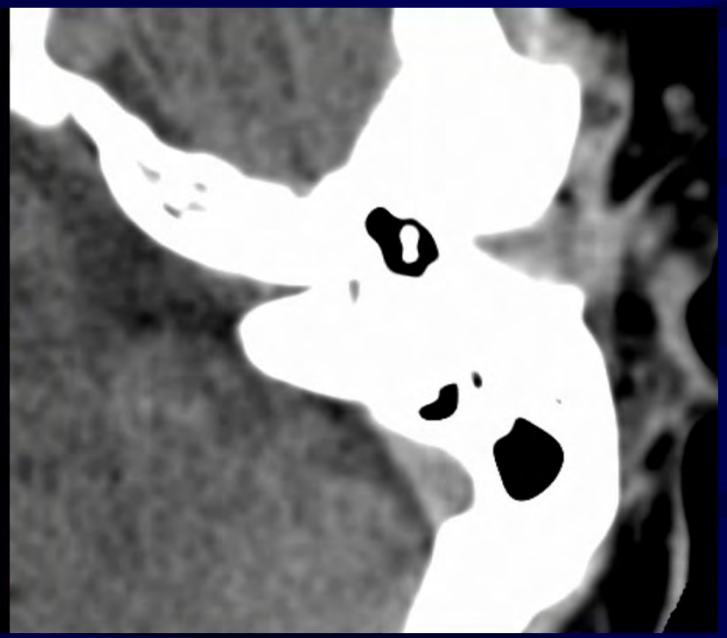

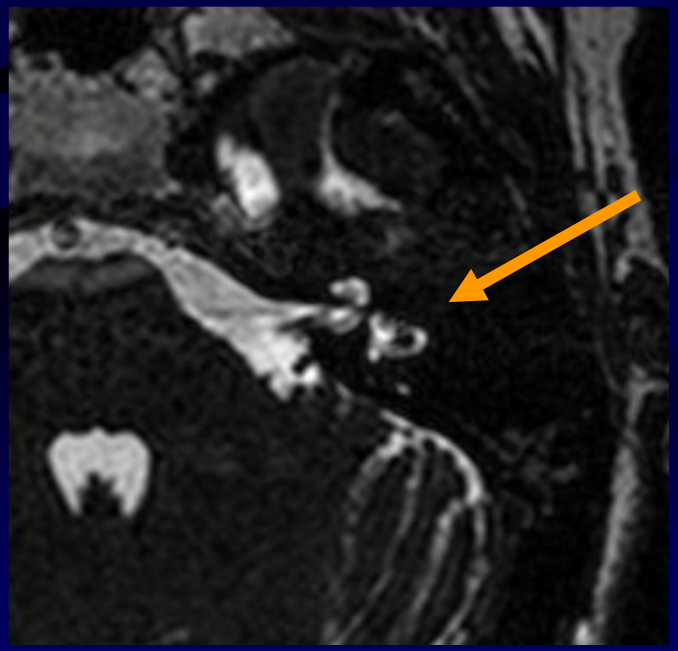

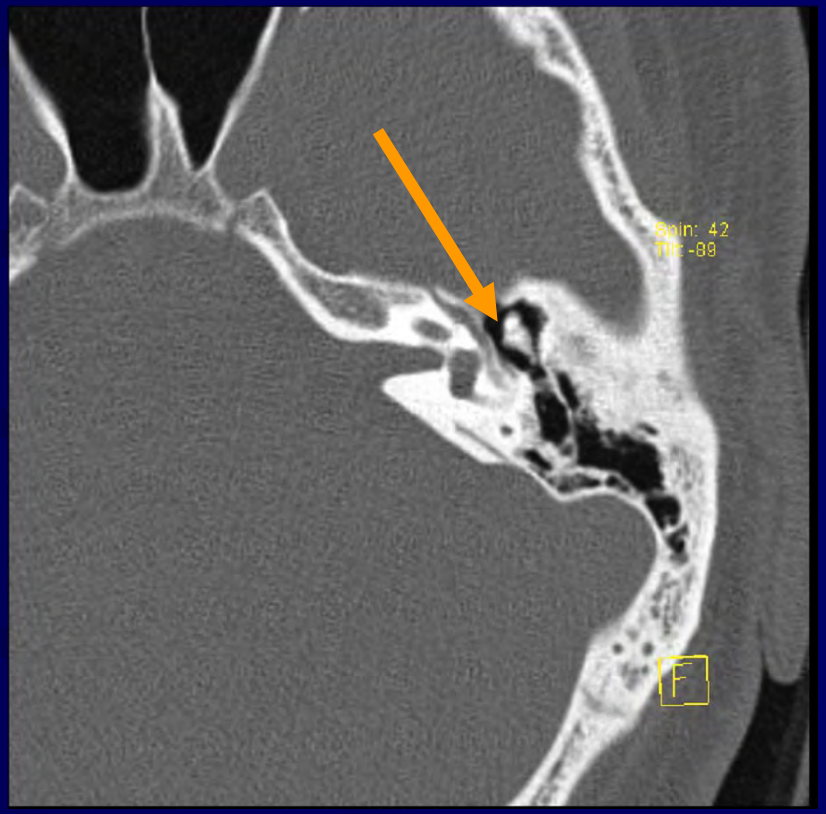
Spin: 42
Tilt: -89
F

TC da COLUNA VERTEBRAL

Aquisição helicoidal

Reconstrução sagital, transversal e coronal

Algoritmo: tecidos moles e ósseo

Contraste iodado iv
intra-tecal (mielo-TC)

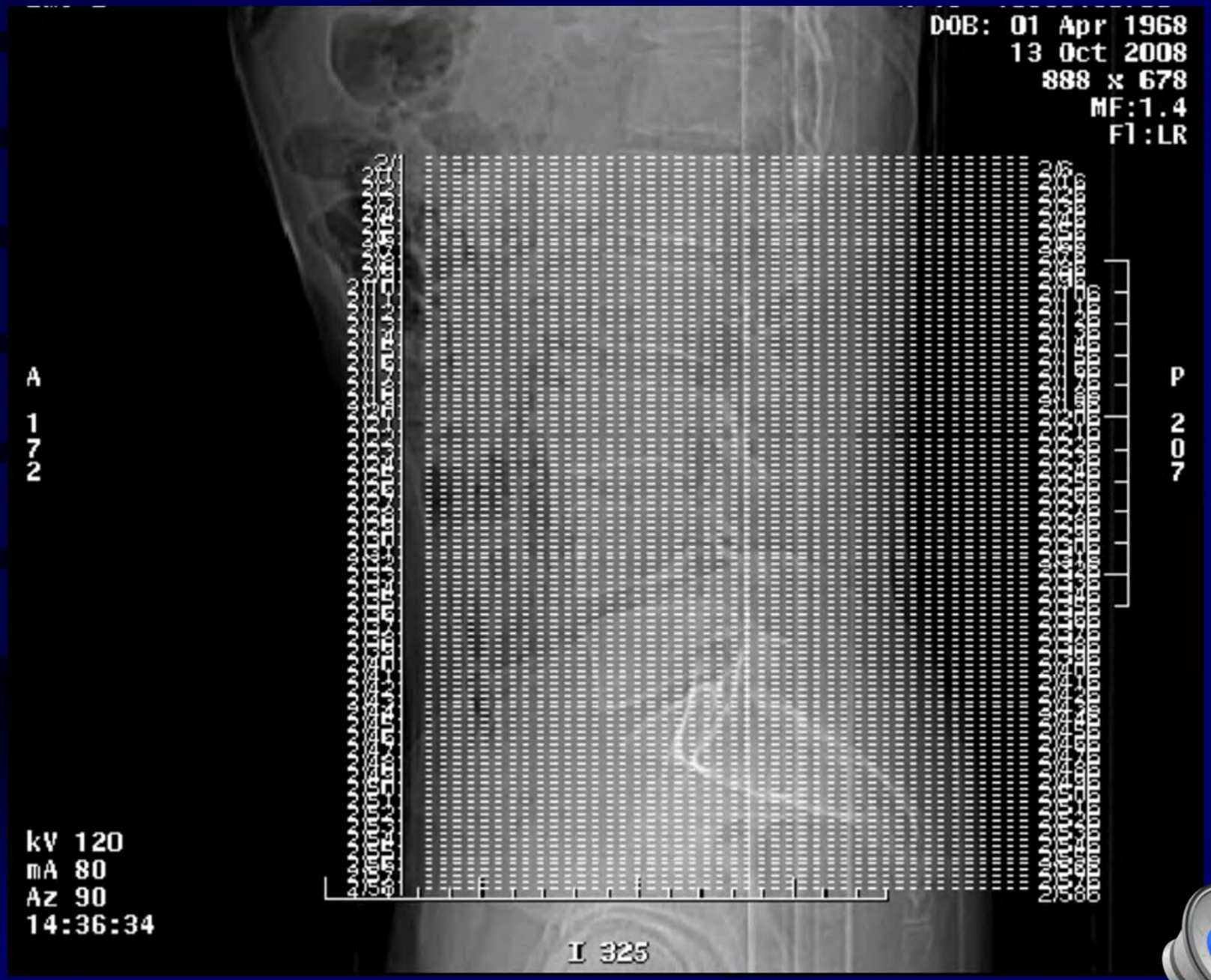
DOB: 01 Apr 1968
13 Oct 2008
888 x 678
MF:1.4
Fl:LR
A
172
P
207
kV 120
mA 80
Az 90
14:36:34
I 325

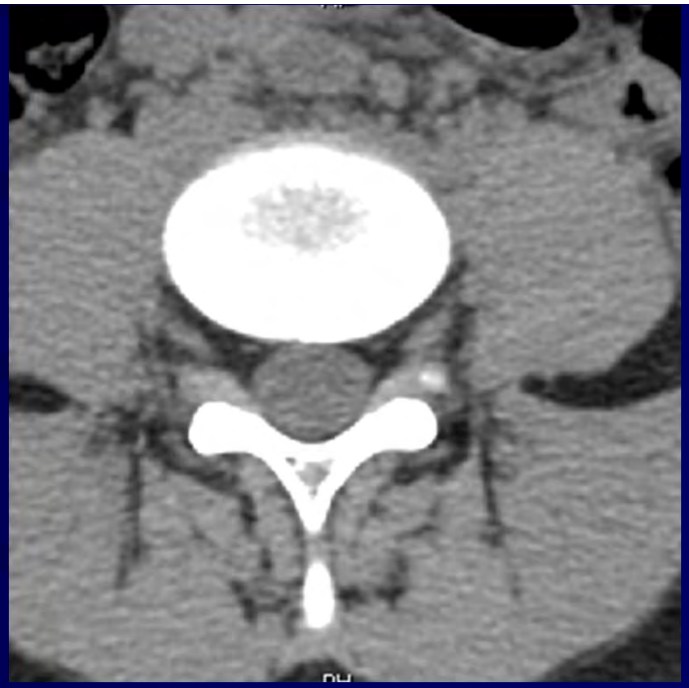

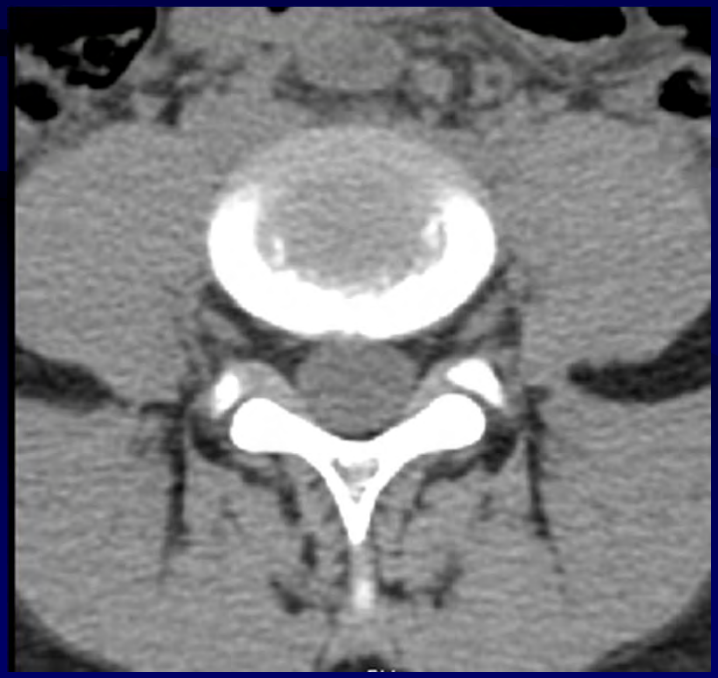

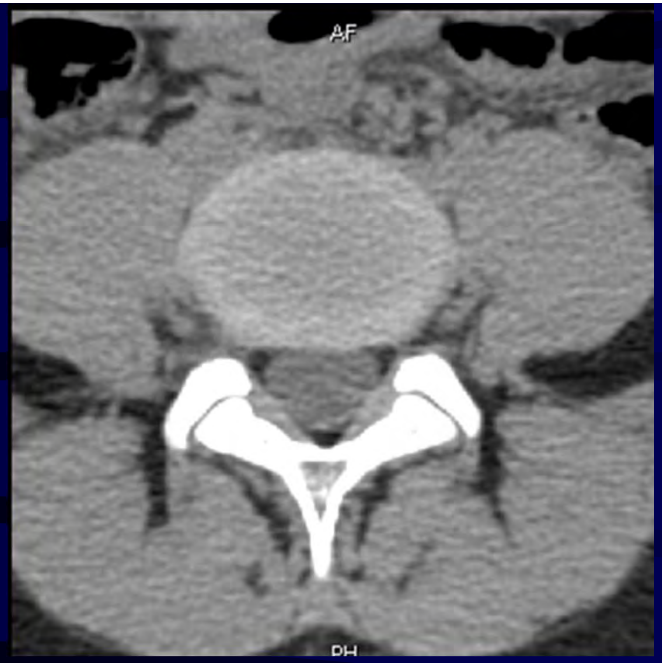
AF
PH

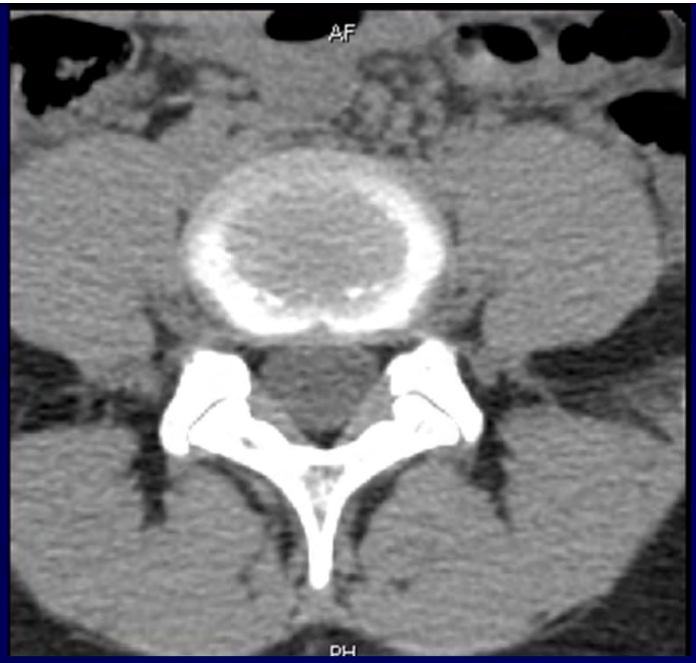
AF
PH

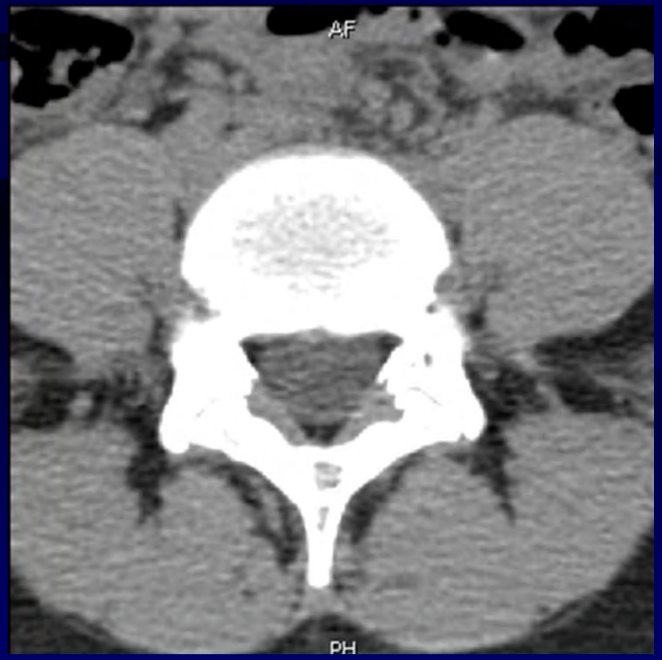
AF
PH

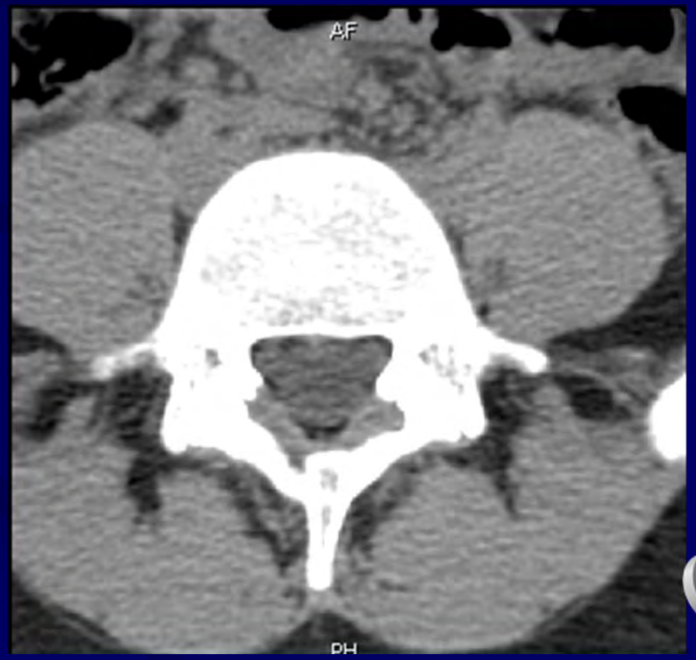
AF
PH

PH

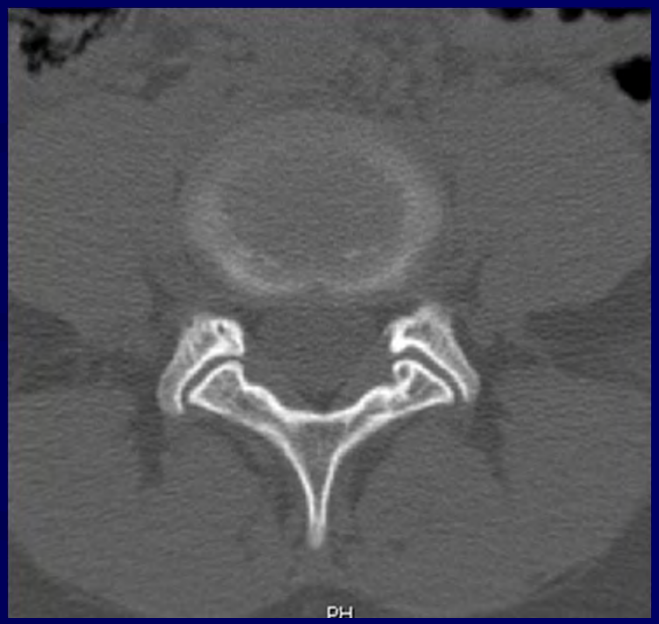
PH

PH

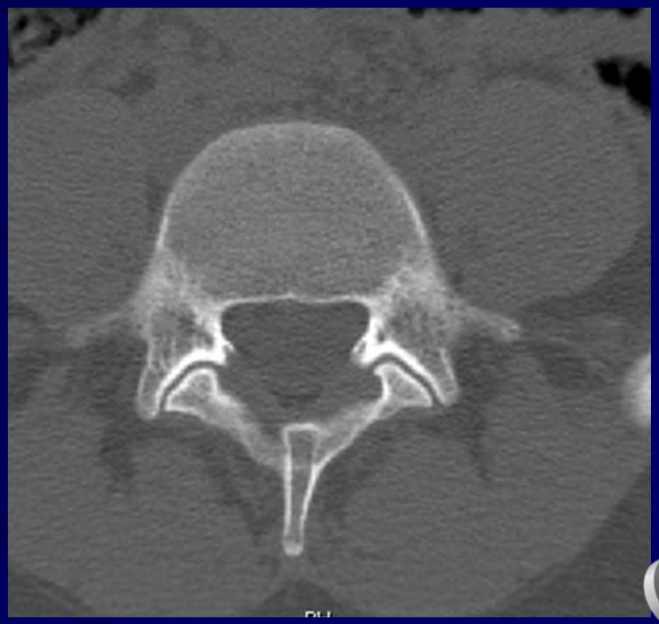

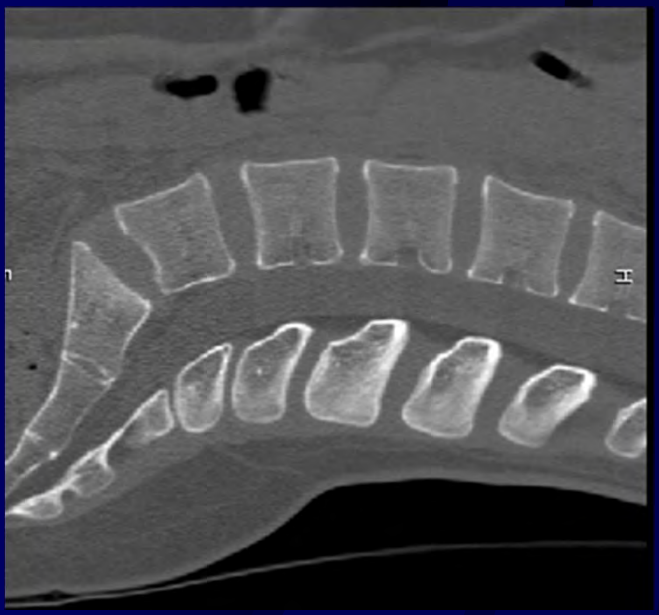

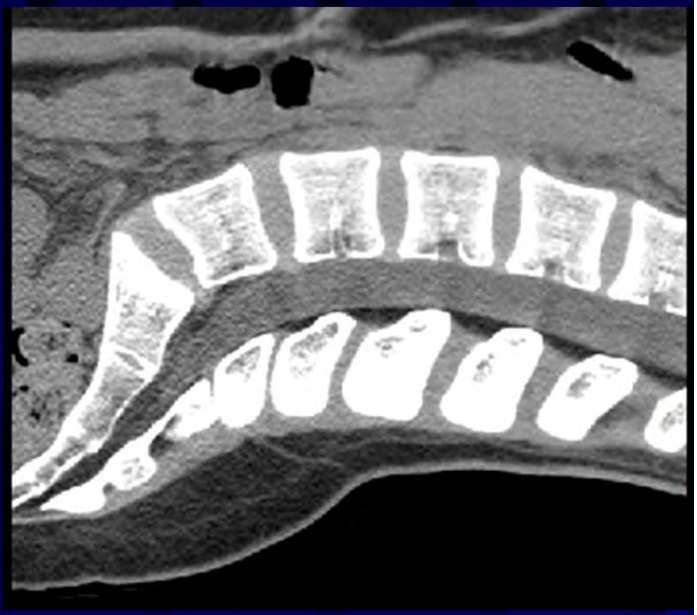

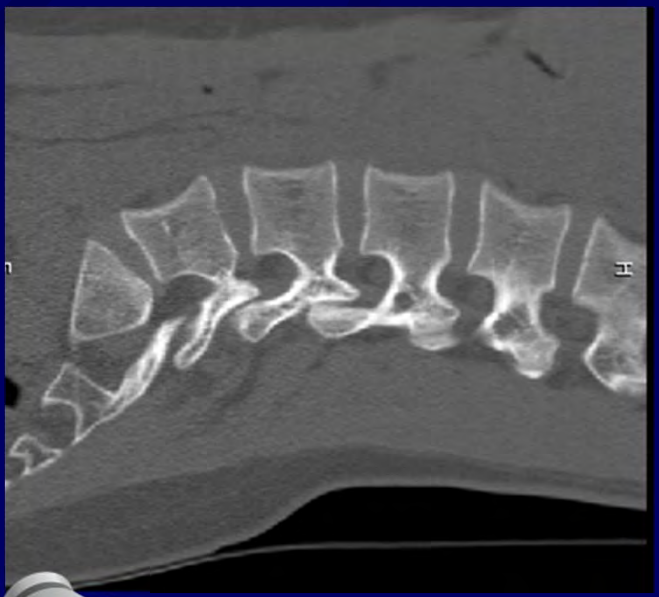

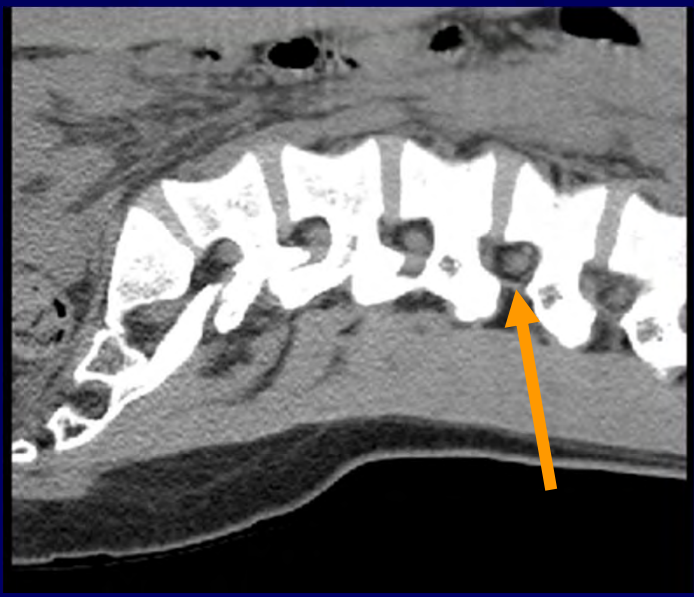

RM VERTEBRO-MEDULAR

Sequências: T1 e T2…
Angio

Planos: Sagitais, axiais, coronais**…**

Contraste paramagnético iv

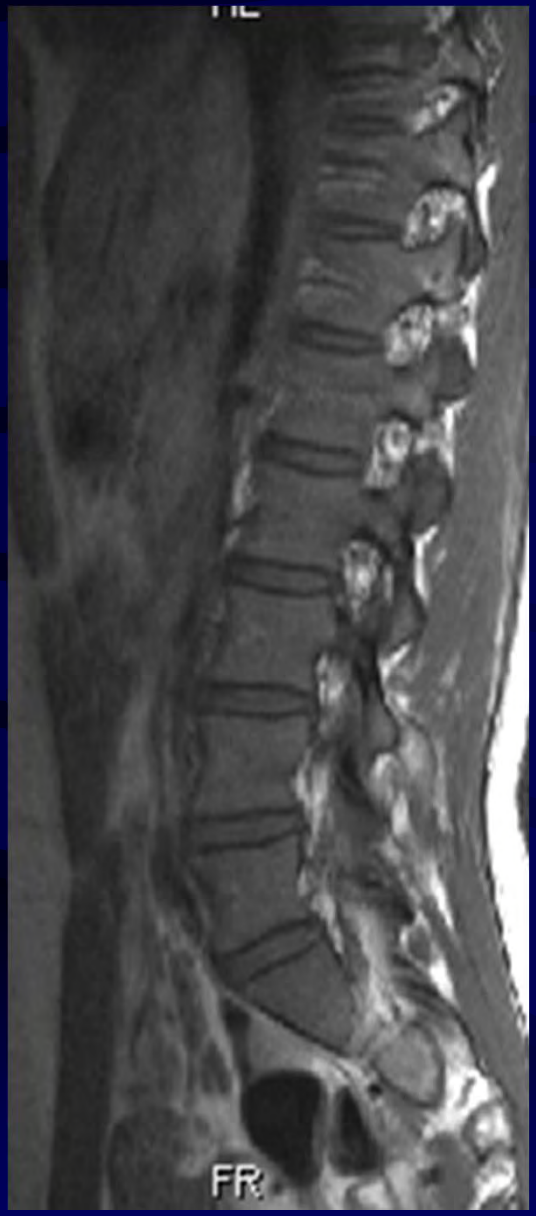
FR

HL
FR

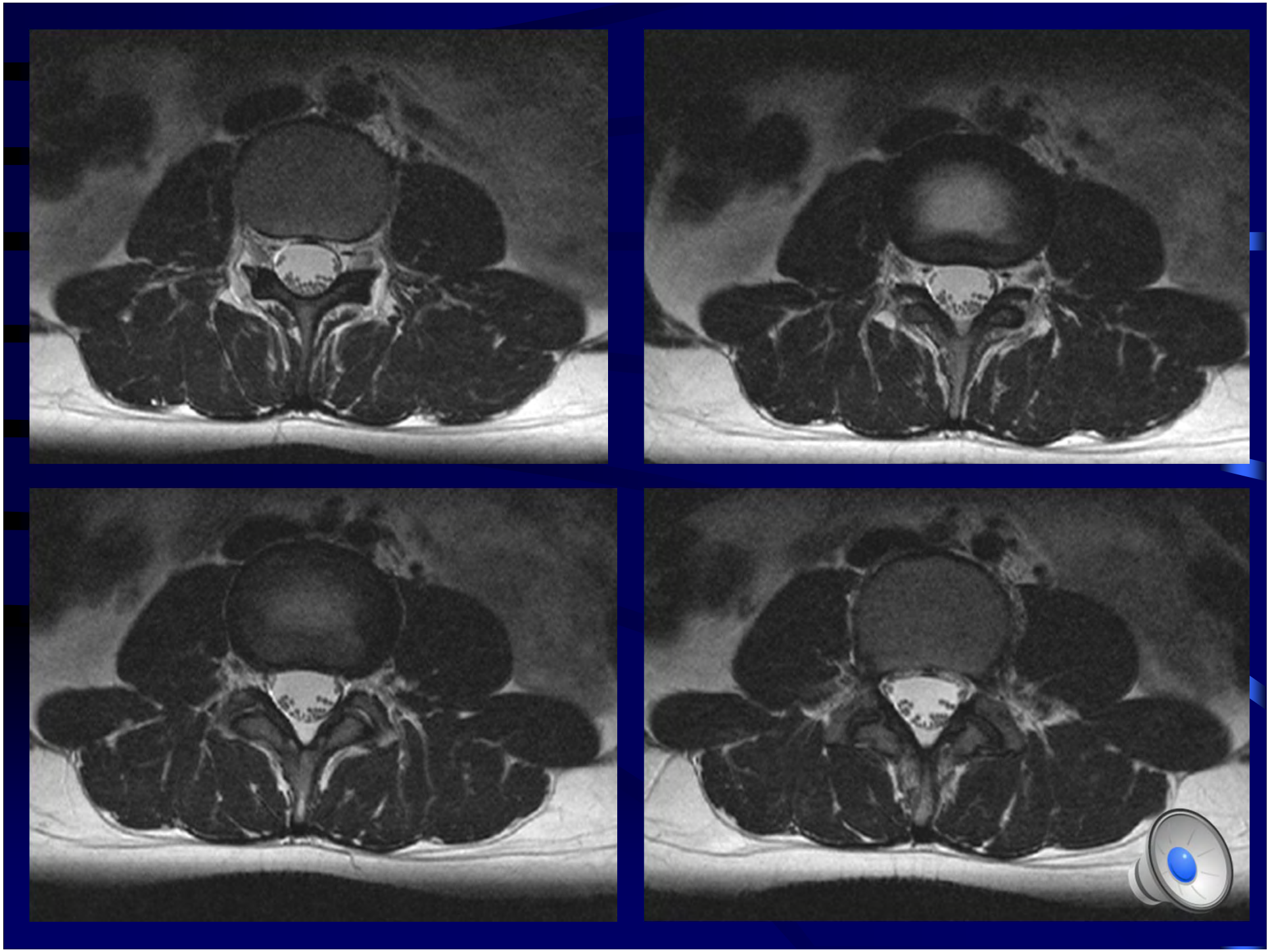

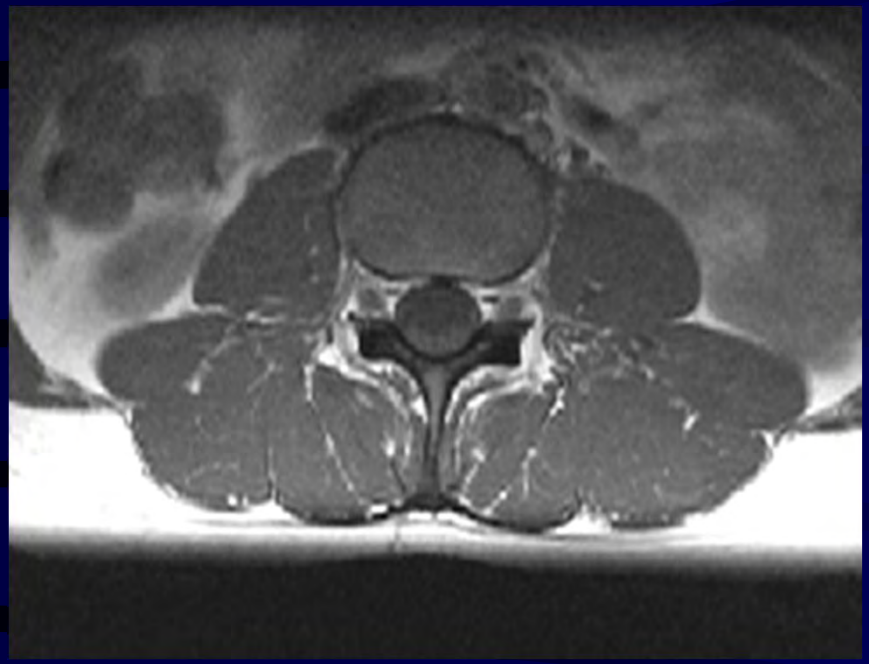

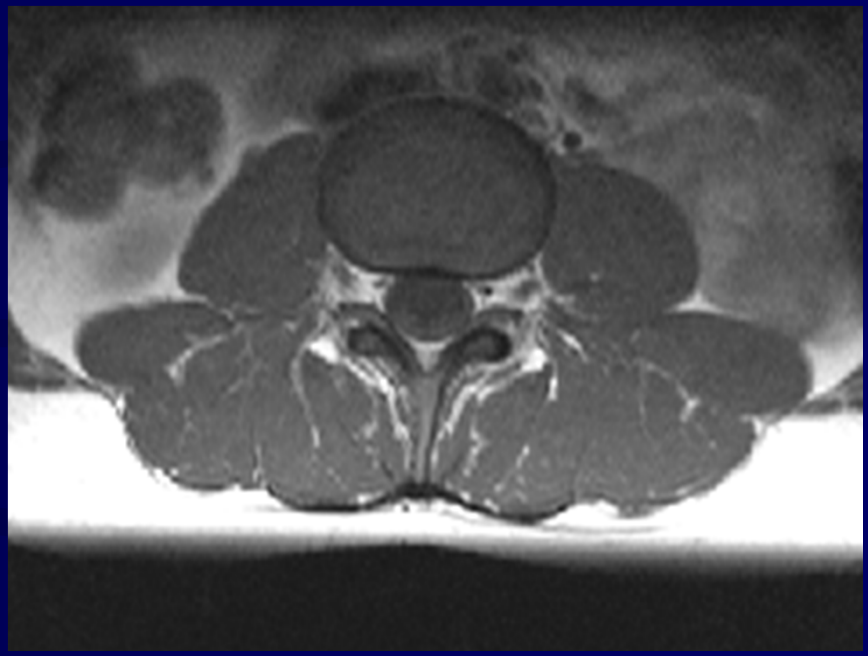

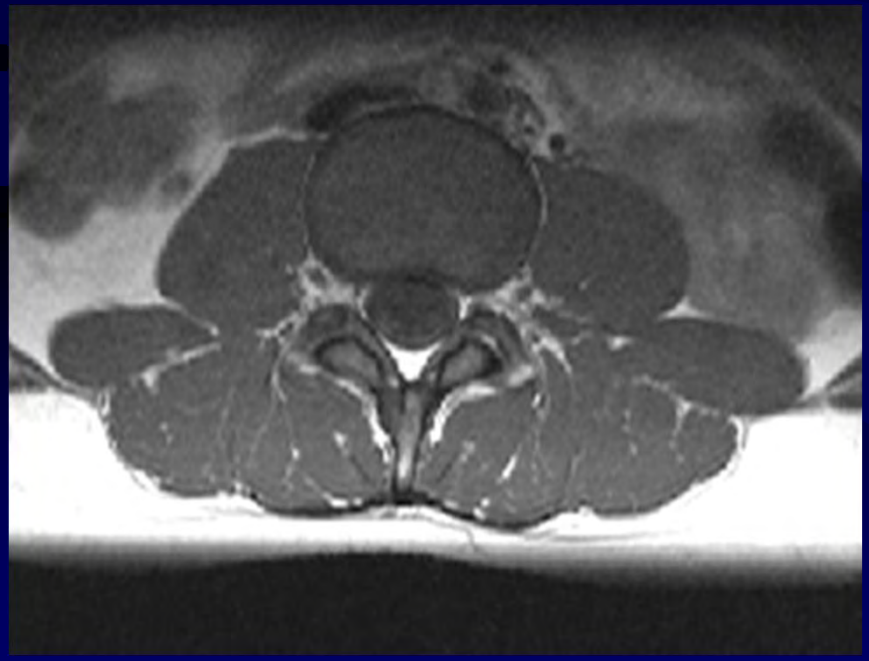

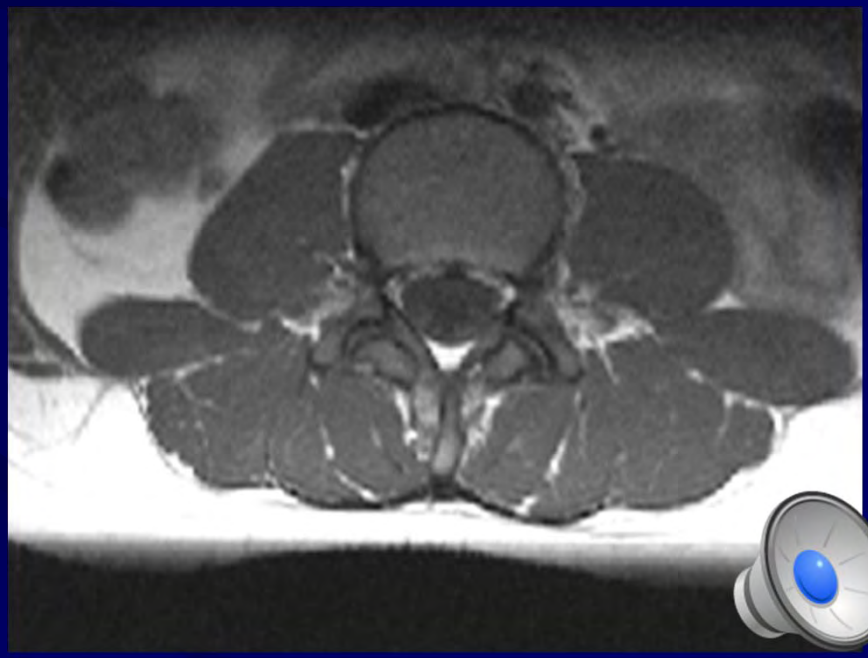

PATOLOGIAS

Vascular isquémica
hemorrágica

Traumática

Tumoral

Inflamatória/Infecciosa

Degenerativa

PATOLOGIA VASCULAR

TC

Exame de 1ª linha na fase aguda

Controlo evolutivo

Técnicas especiais

Perfusão

Angio-TC

RM

Complementar

AVC do tronco cerebral

Técnicas especiais

- Difusão
- Perfusão
- Angio-RM

Quadro súbito de hemiplegia esquerda

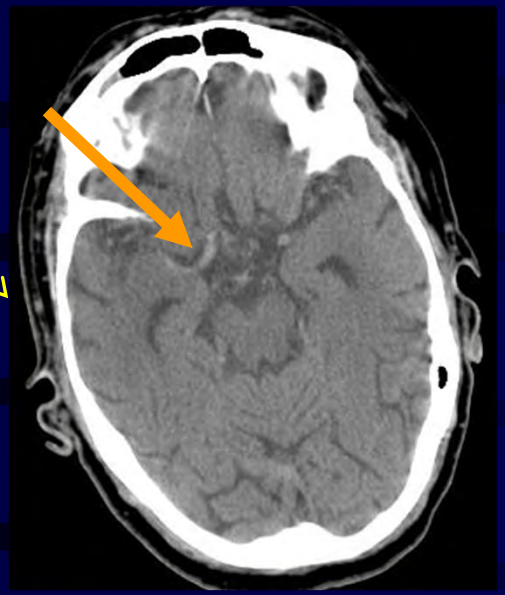

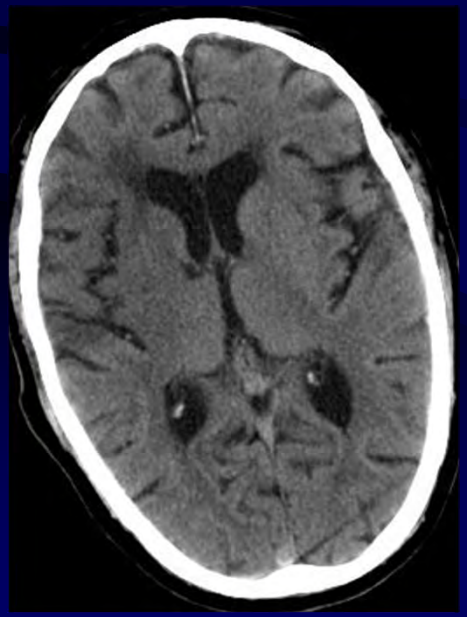

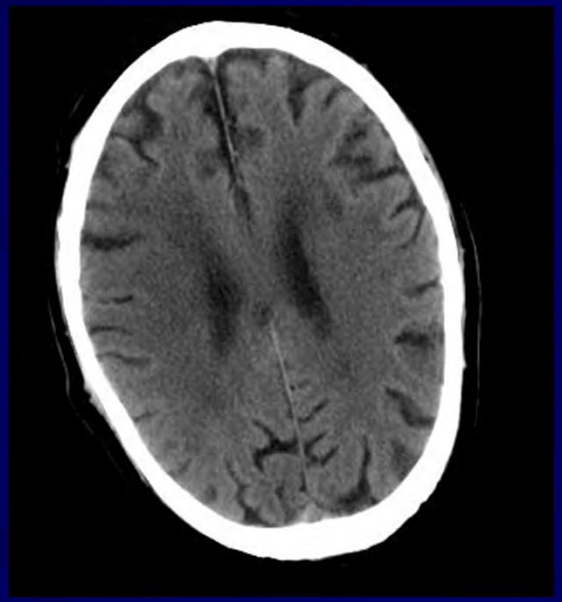

2ºdia

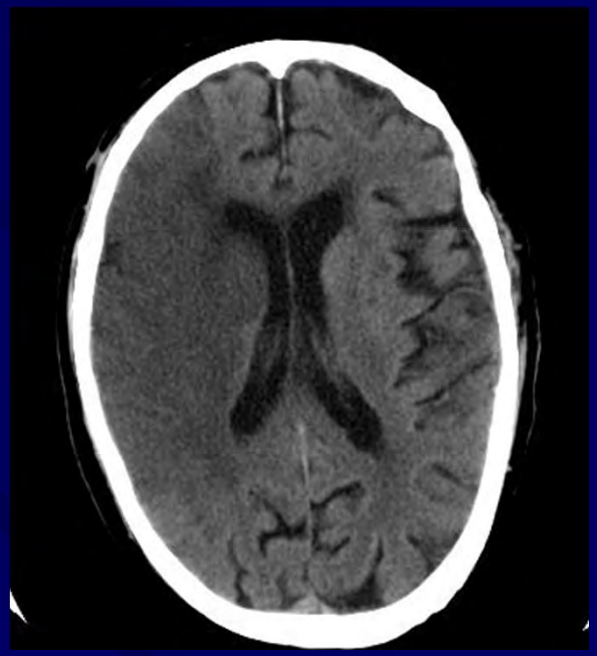

Hemiparésia direita com 2 h de evolução

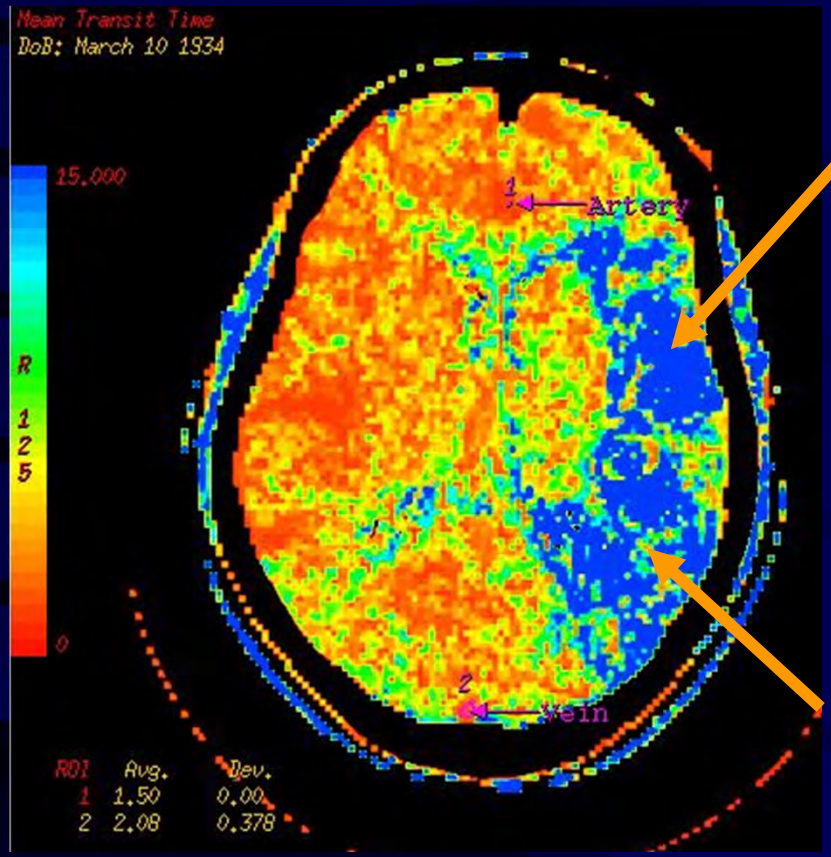
Mean Transit Time
DoB: March 10 1934
15.000
R
1
2
5
0
1
Artery
2
Vein
ROI Avg. Dev.
1 1.50 0.00
2 2.08 0.378

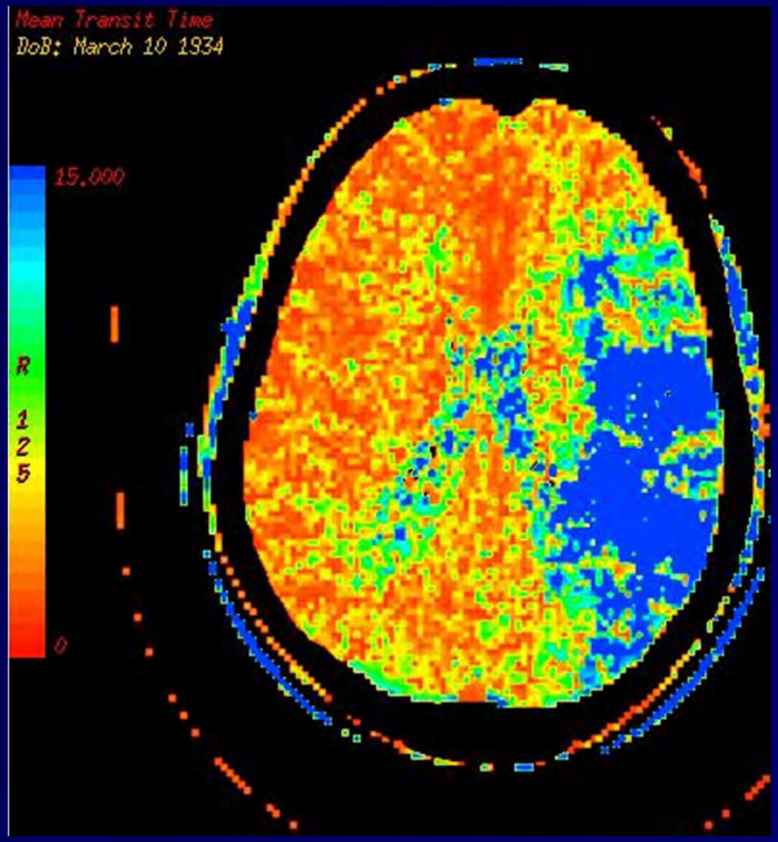
Mean Transit Time
DoB: March 10 1934
15.000
R
1
2
5
0

MTT

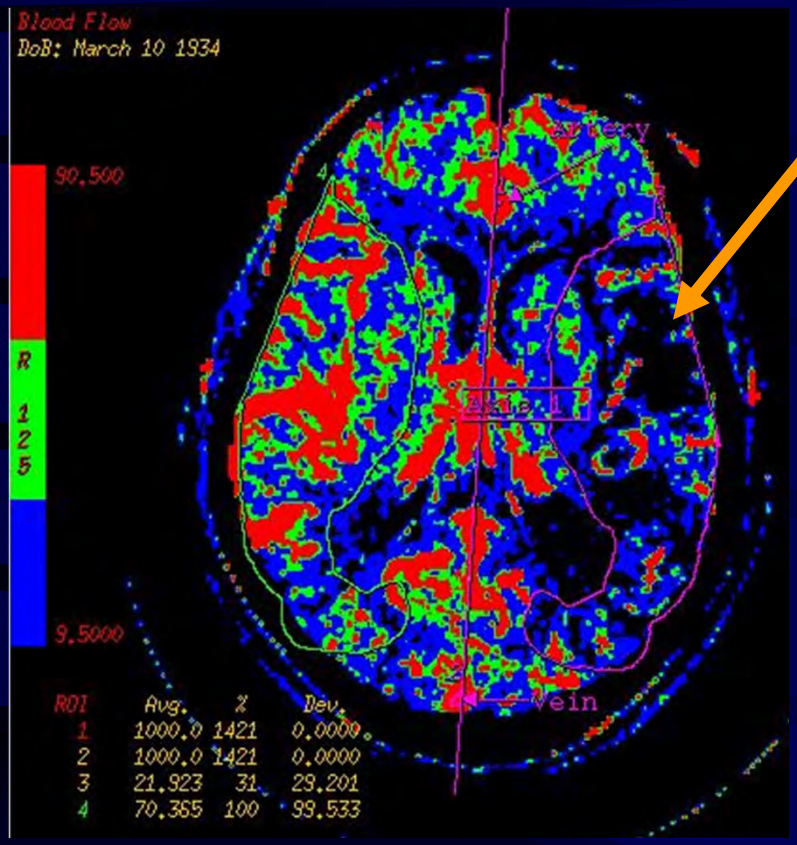
Blood Flow
DoB: March 10 1934
90.500
R
1
2
5
9.5000
Vein
ROI Avg. % Dev.
1 1000.0 1421 0.0000
2 1000.0 1421 0.0000
3 21.923 31 29.201
4 70.365 100 99.533

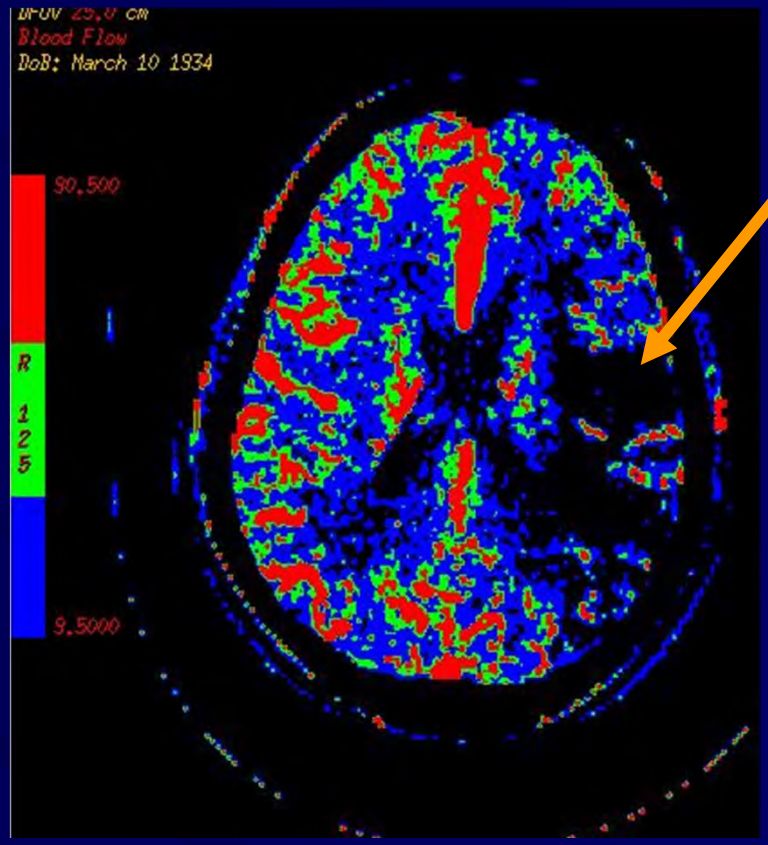
Blood Flow
DoB: March 10 1934
90.500
R
1
2
5
9.5000

CBF

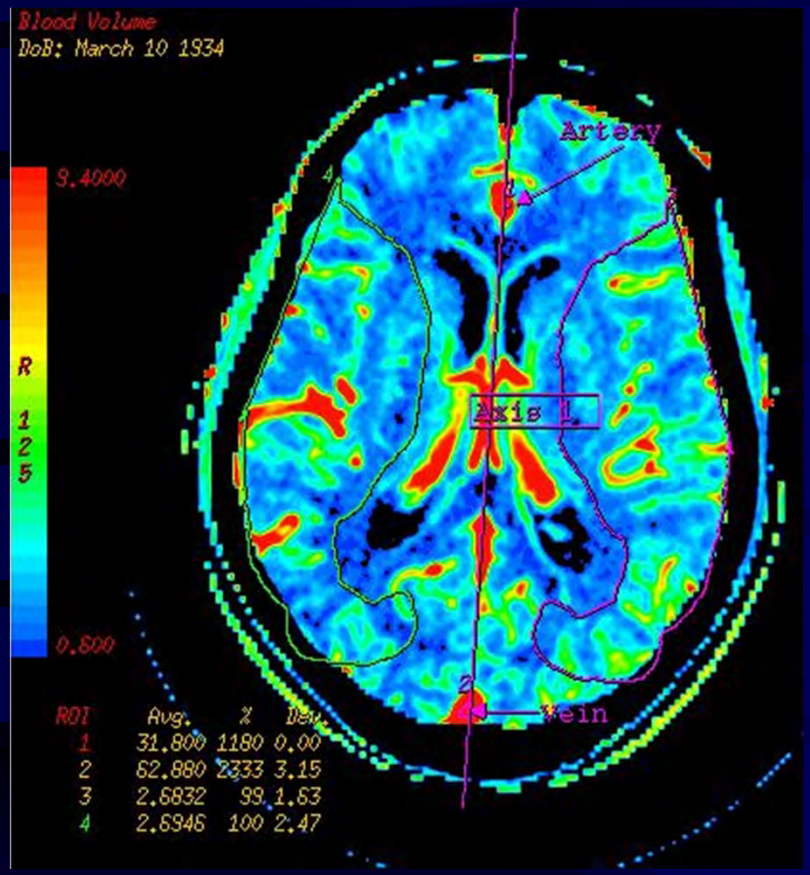
Blood Volume
DoB: March 10 1934
9.4000
R
1
2
5
0.800
Artery
Axis 1
Vein
ROI Avg. % Dev.
1 31.800 1180 0.00
2 62.880 2333 3.15
3 2.6832 99 1.63
4 2.6946 100 2.47

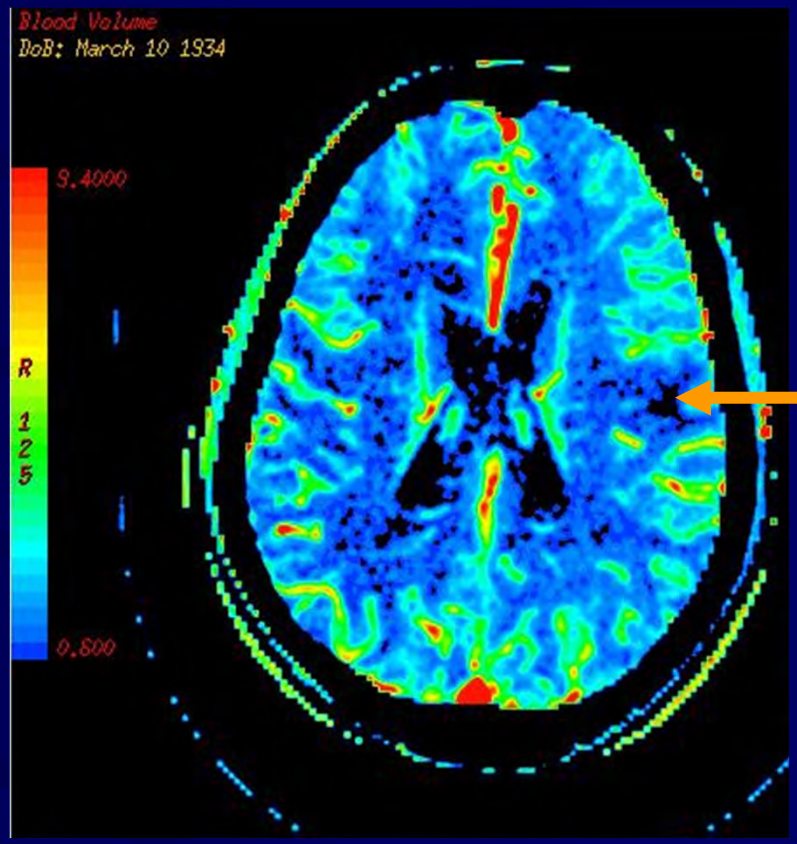
Blood Volume
DoB: March 10 1934
9.4000
R
1
2
5
0.800

CBV

Cefaleia súbita, alteração do estado de consciência

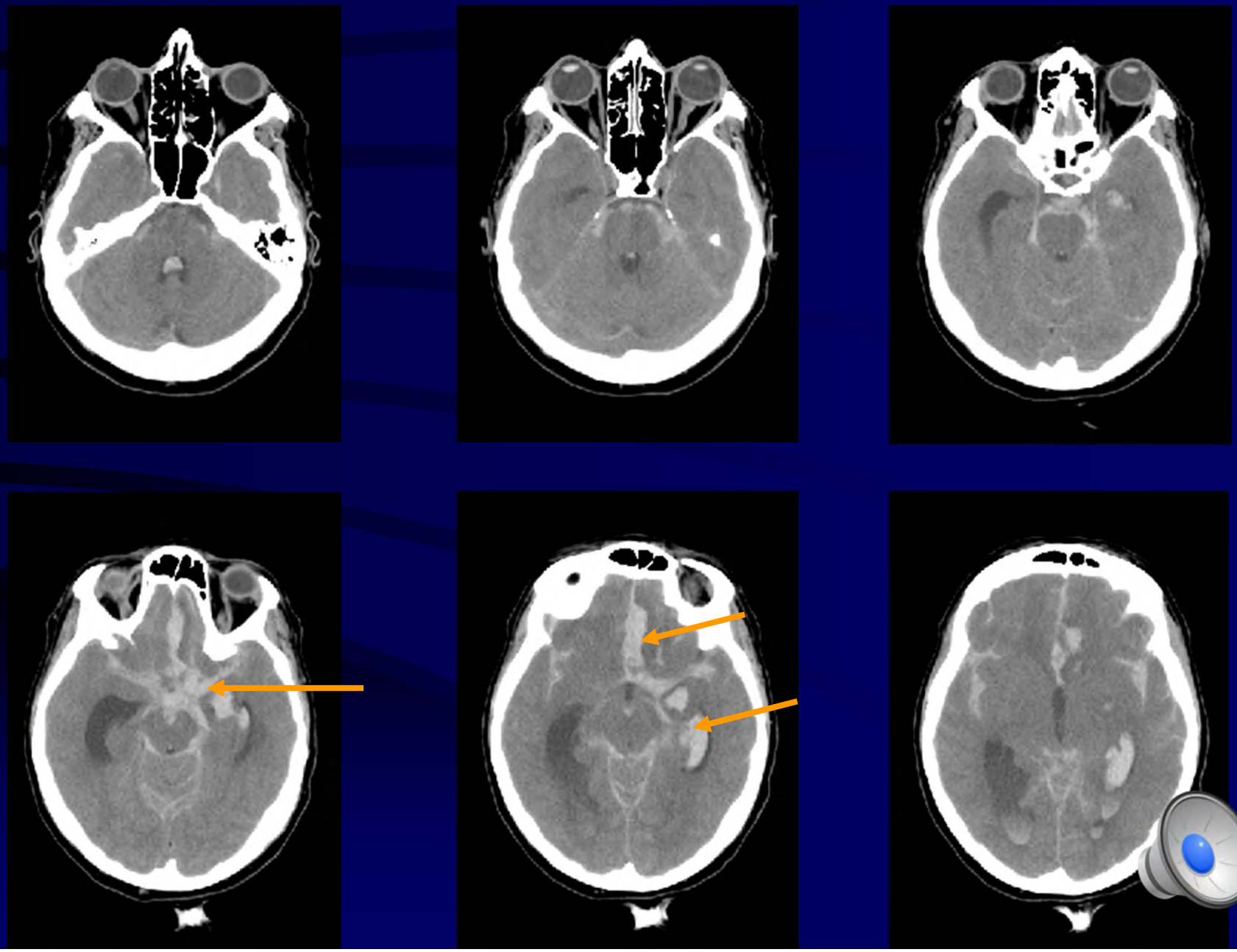

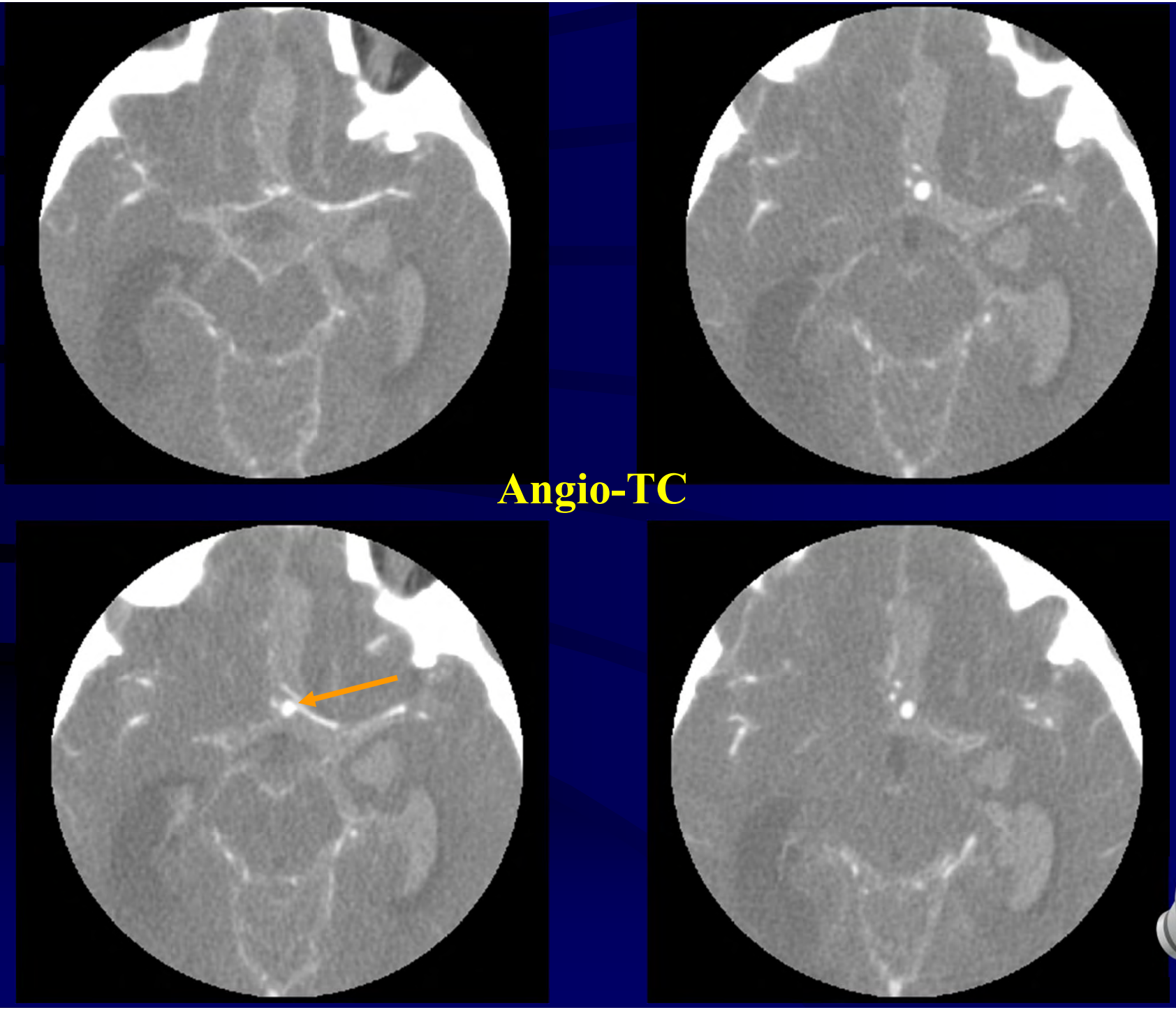
Angio-TC

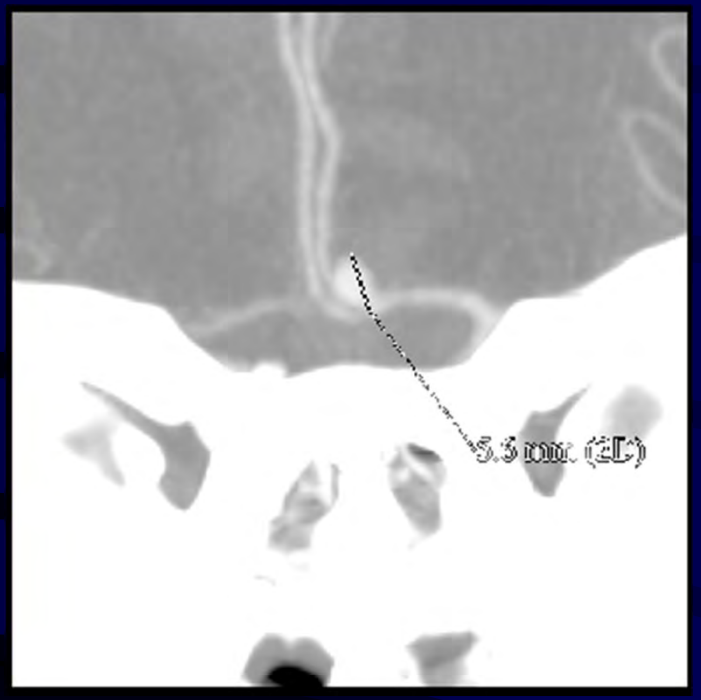

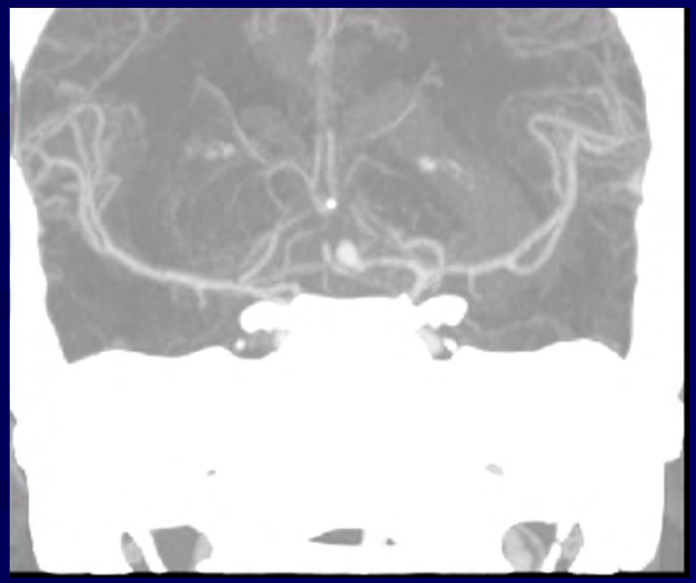

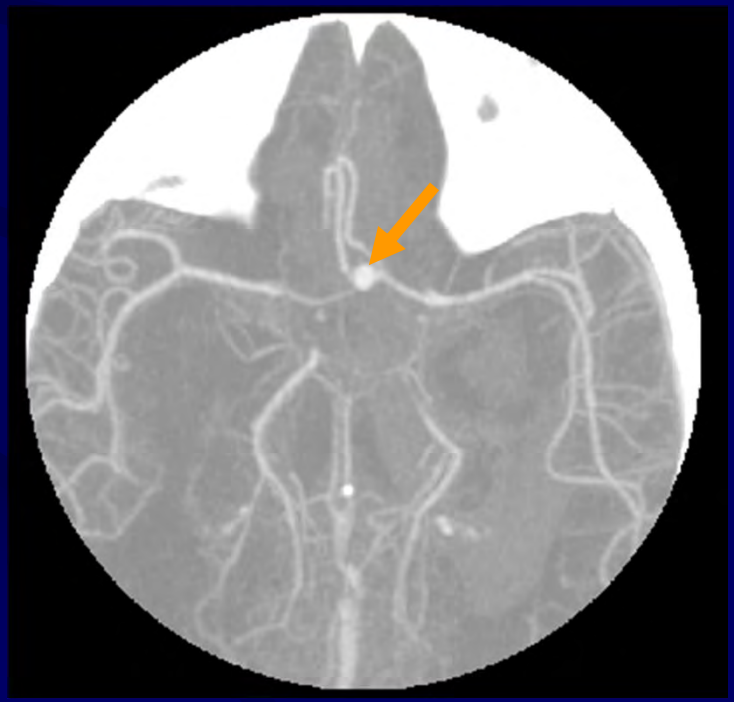

MIP

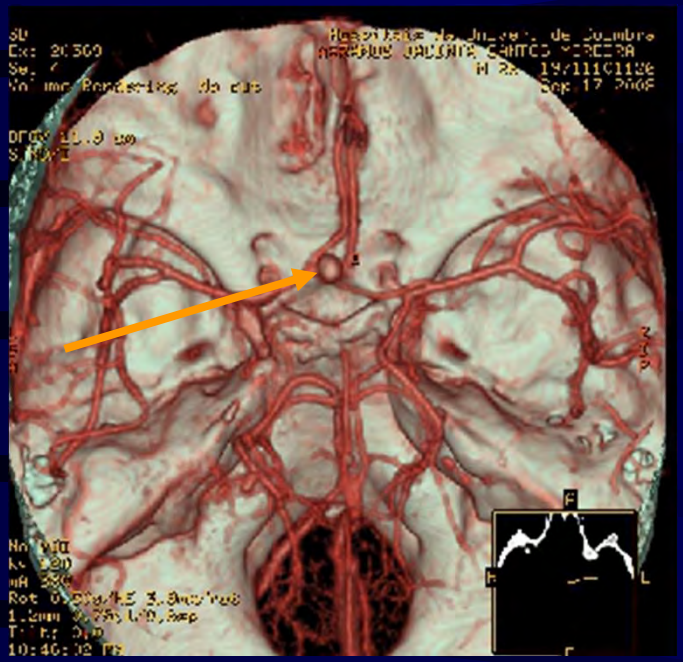

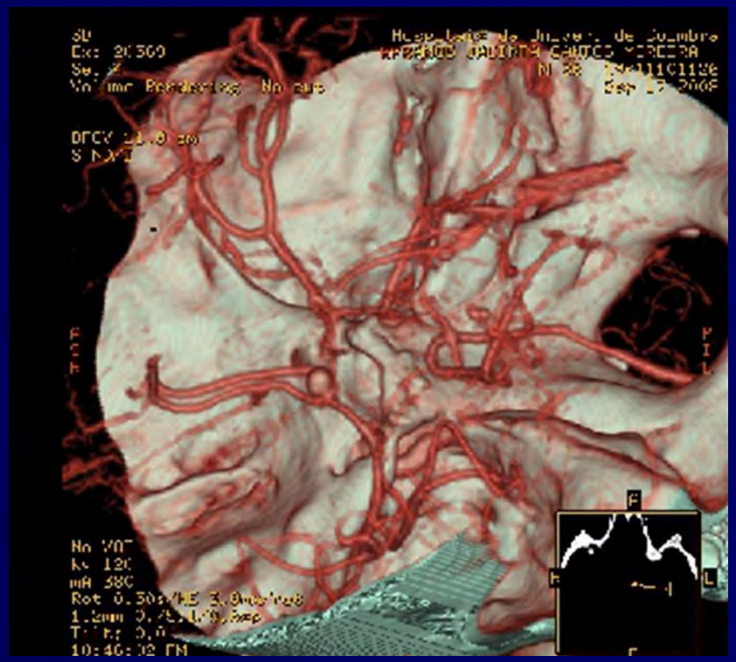

VR

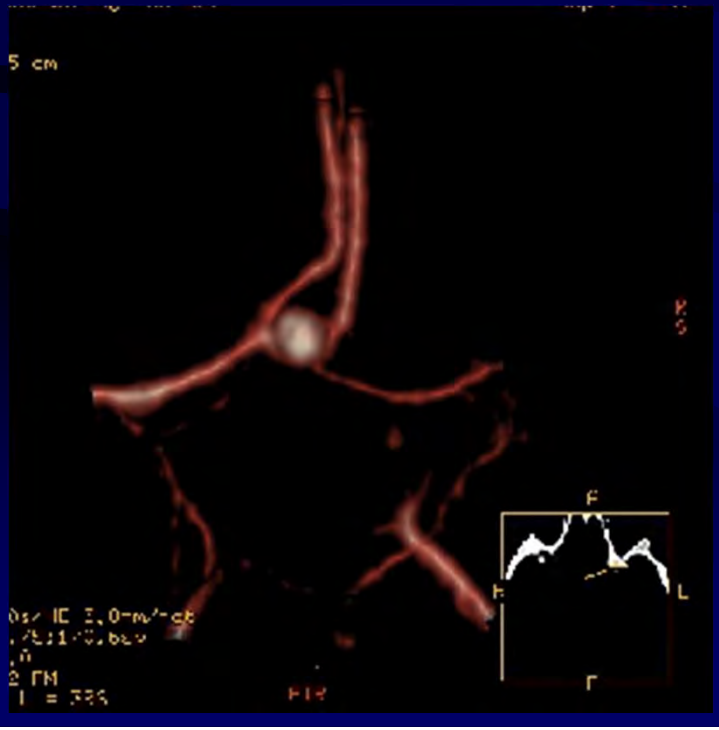

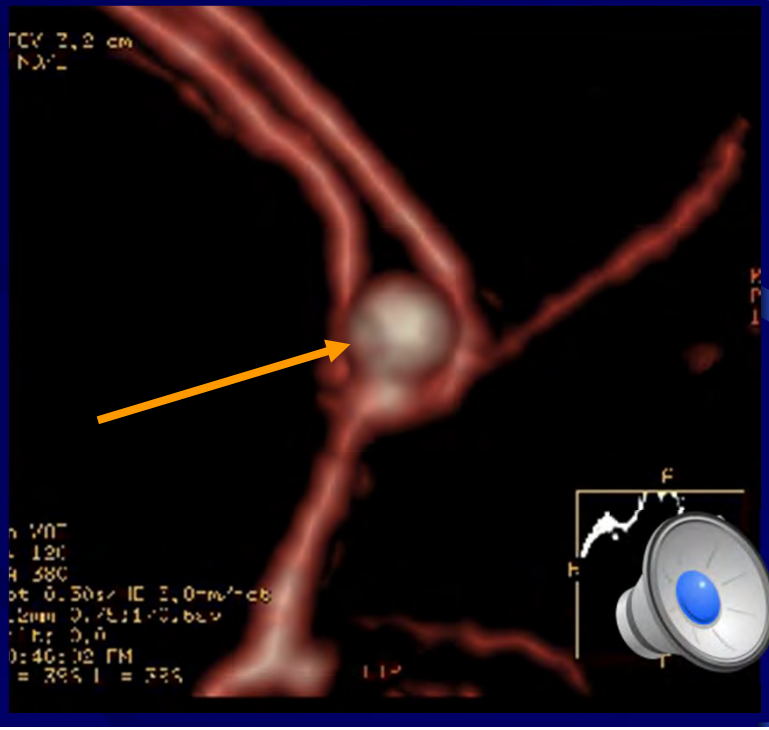

♀, 26 anos
Cefaleias e vómitos de inicio súbito há 2 dias
Contraceptivos orais
Hemiparésia esq. e defeito de campo visual esq.

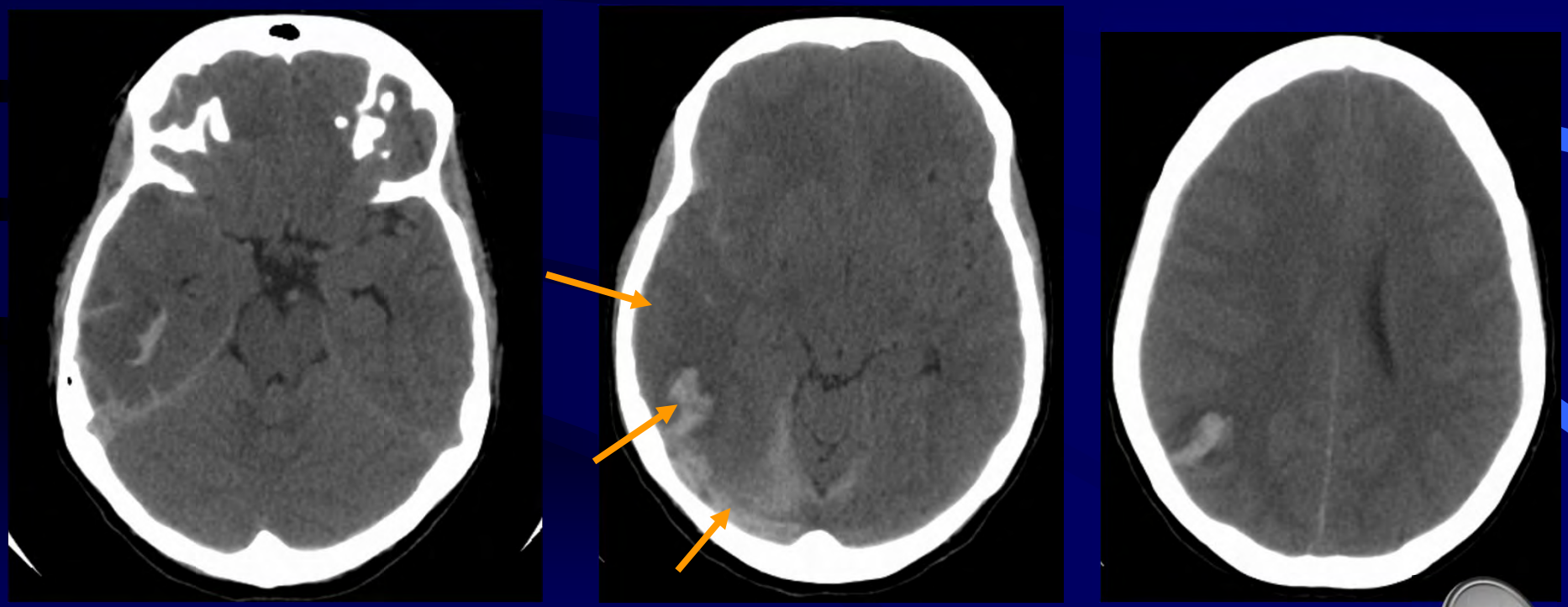

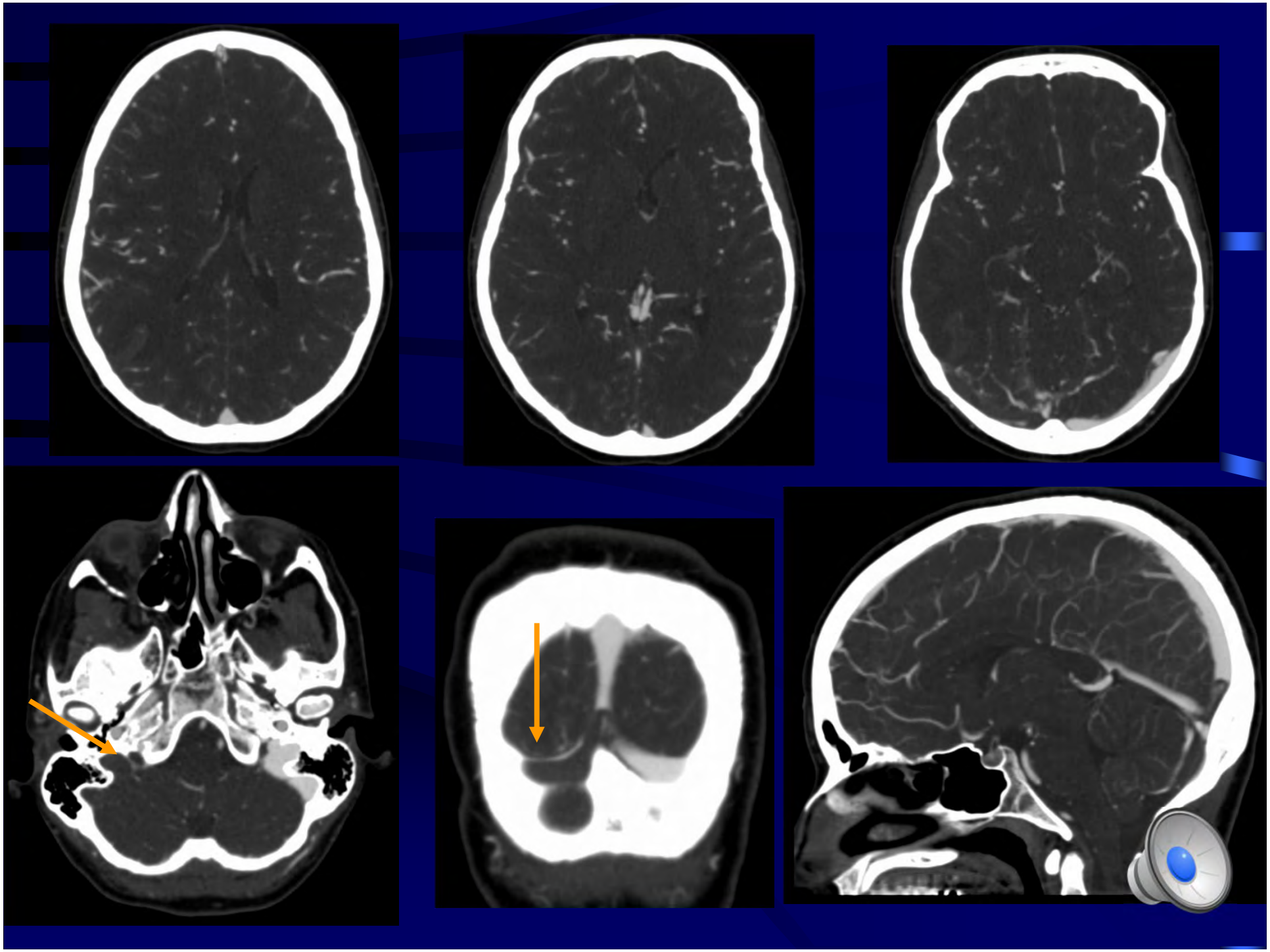

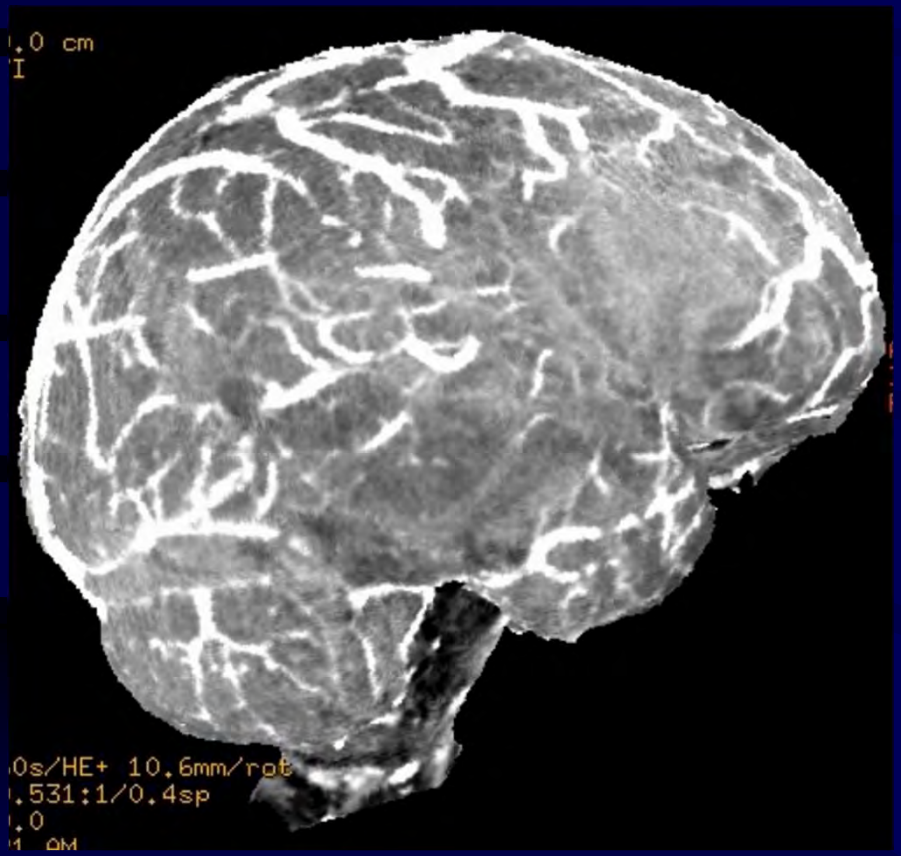
.0 cm
0s/HE+ 10.6mm/rot
.531:1/0.4sp
.0

cm
HE+ 10.6mm/rot
1:1/0.4sp

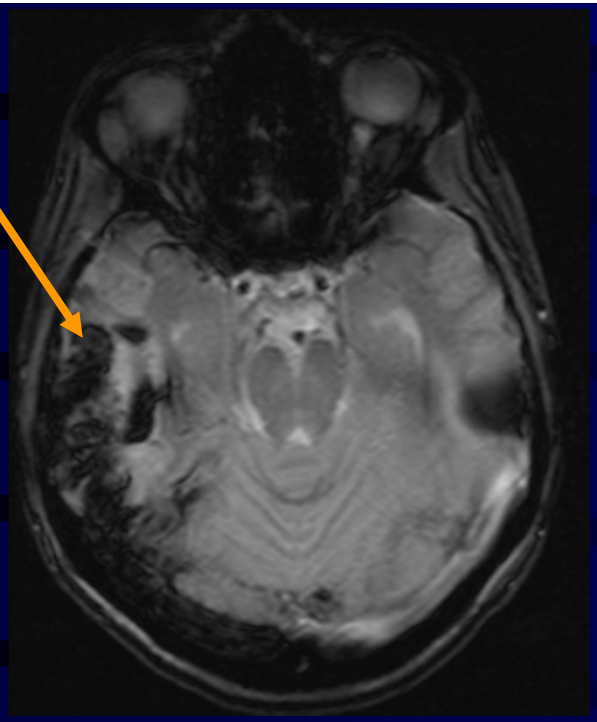

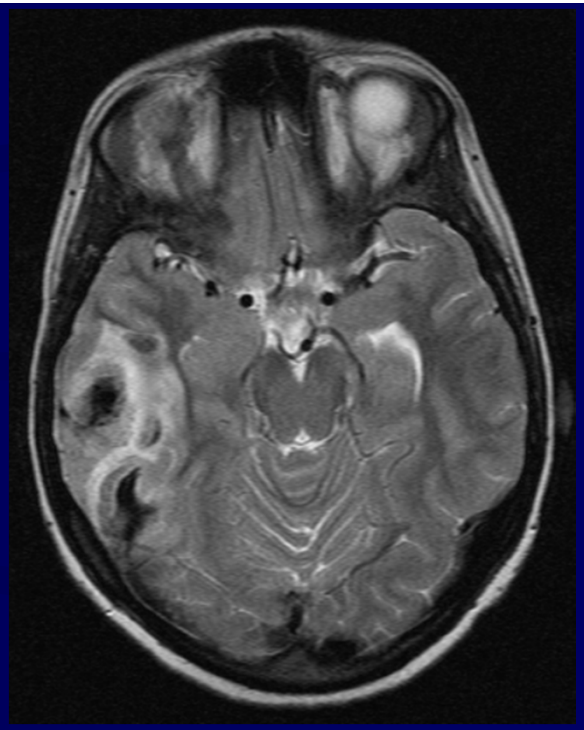

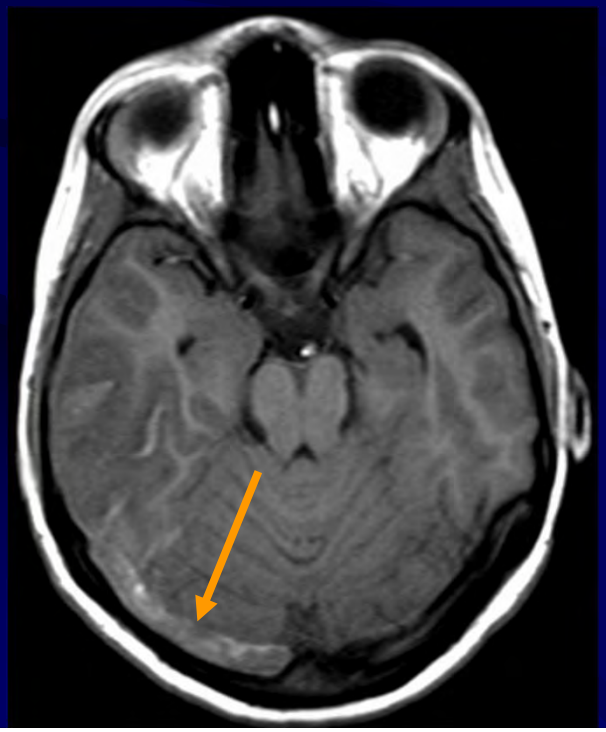

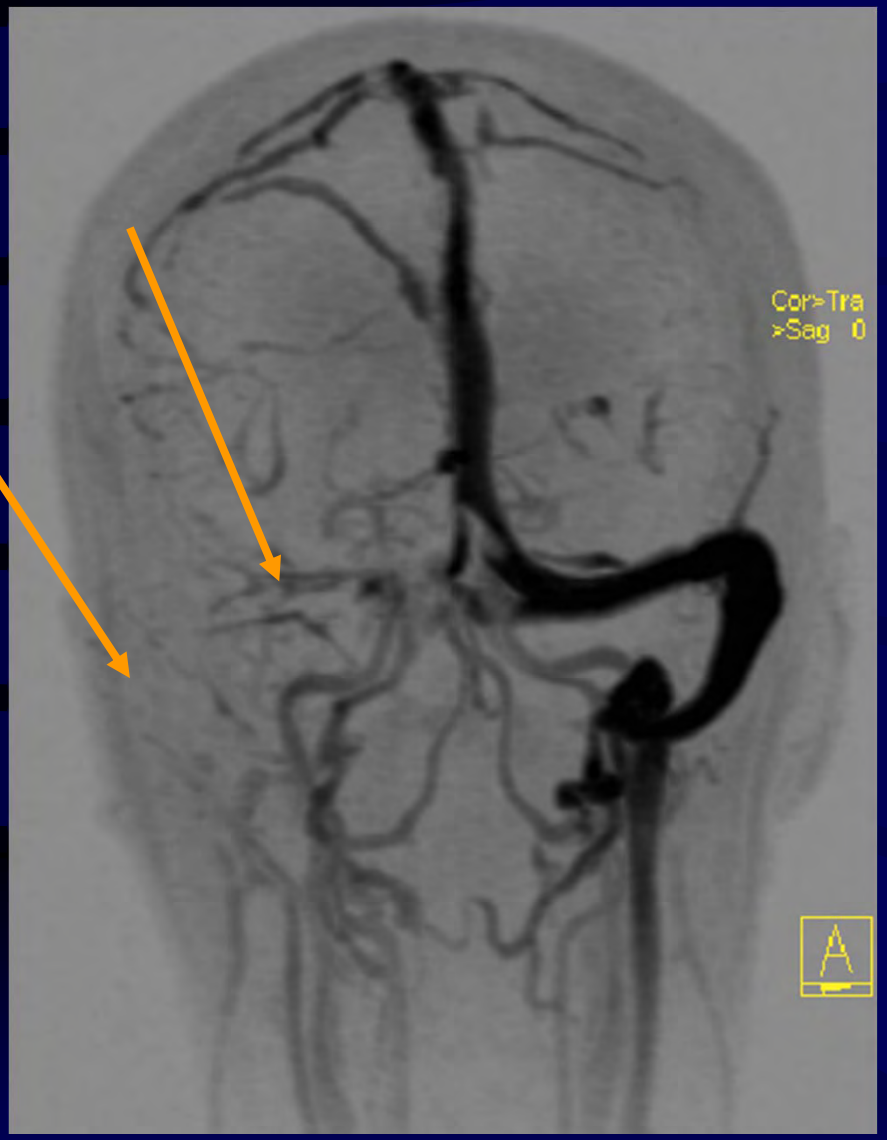
Cor>Tra
>Sag 0
A

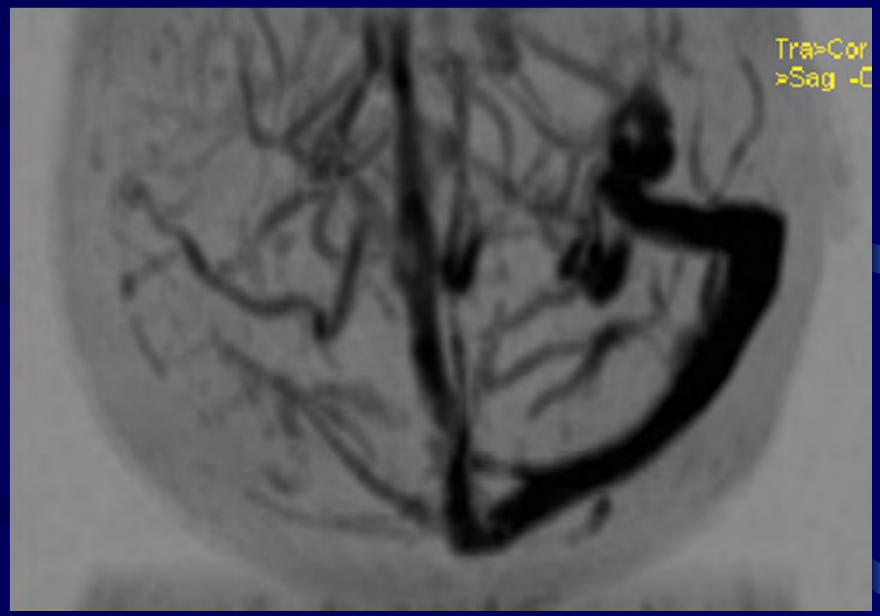
Tra>Cor
>Sag -C

PATOLOGIA TRAUMÁTICA

RX

Trauma vertebral

TC

1ª linha

lesões cerebrais

caracterização das fracturas

RM

Traumatismos vertebro-medulares

TCE lesões axonais difusas

TCE

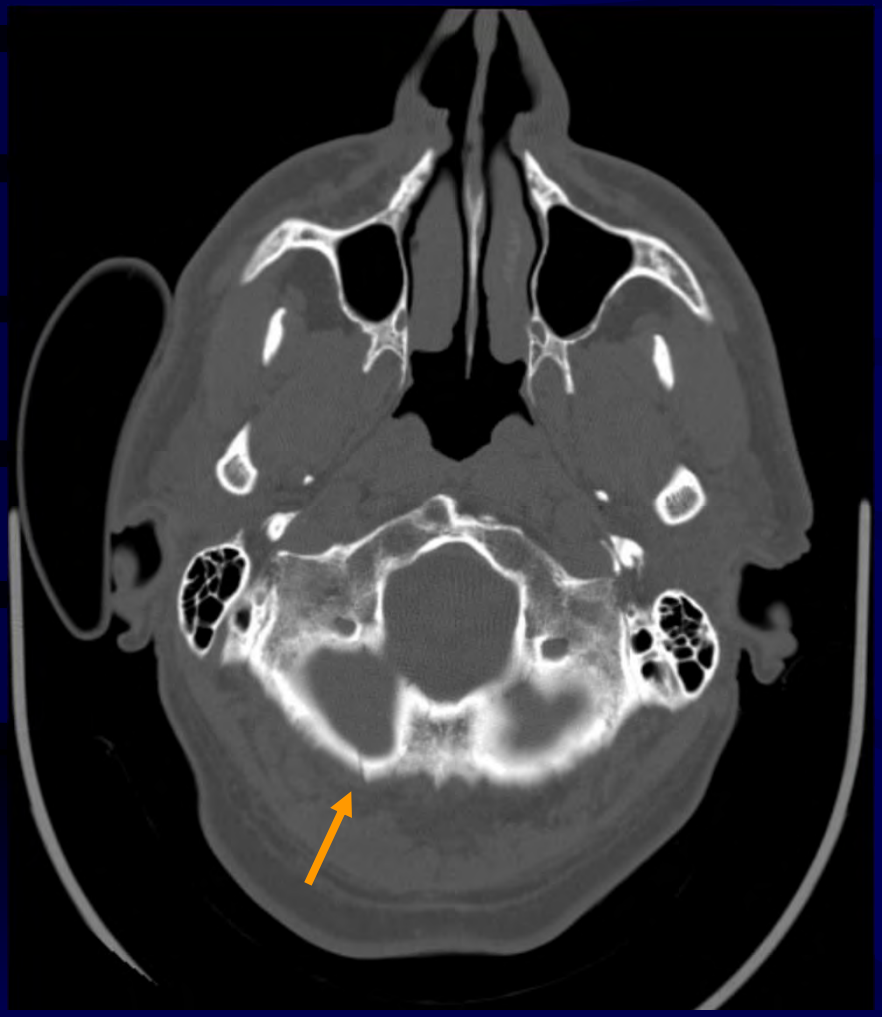

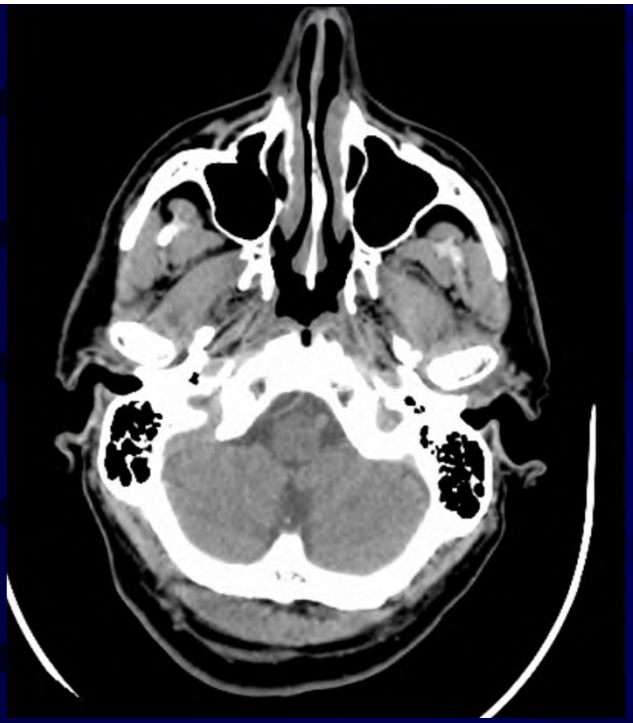

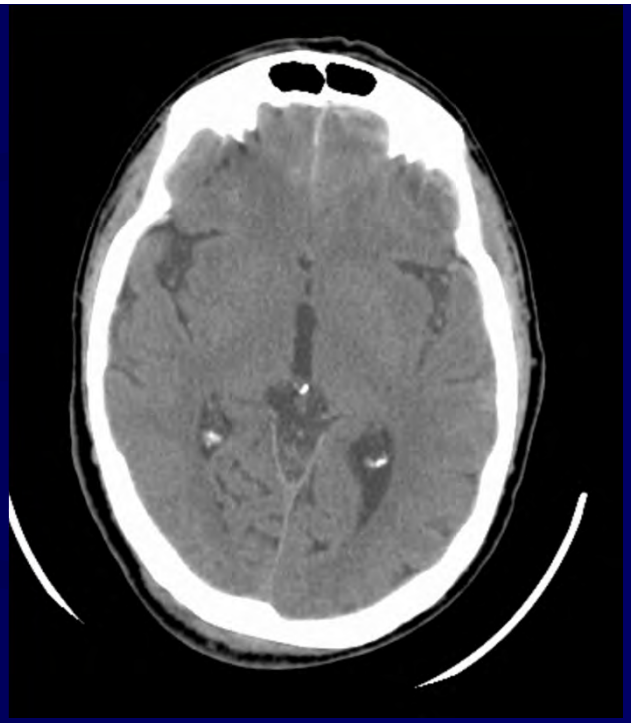

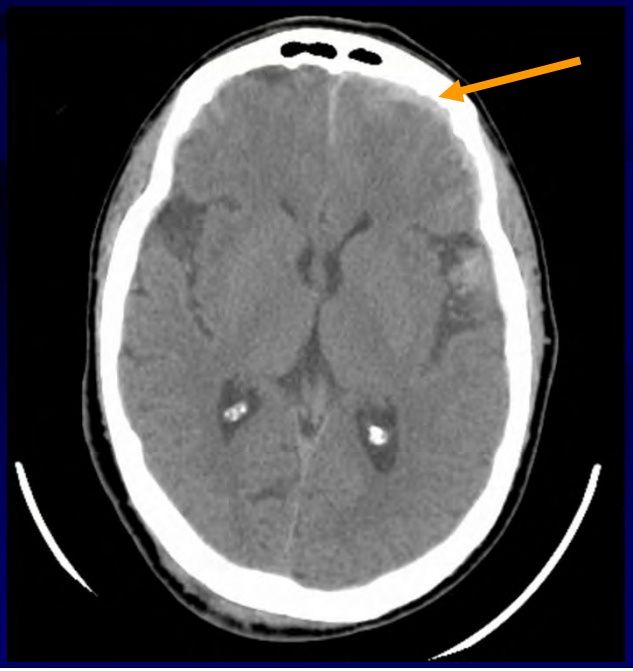

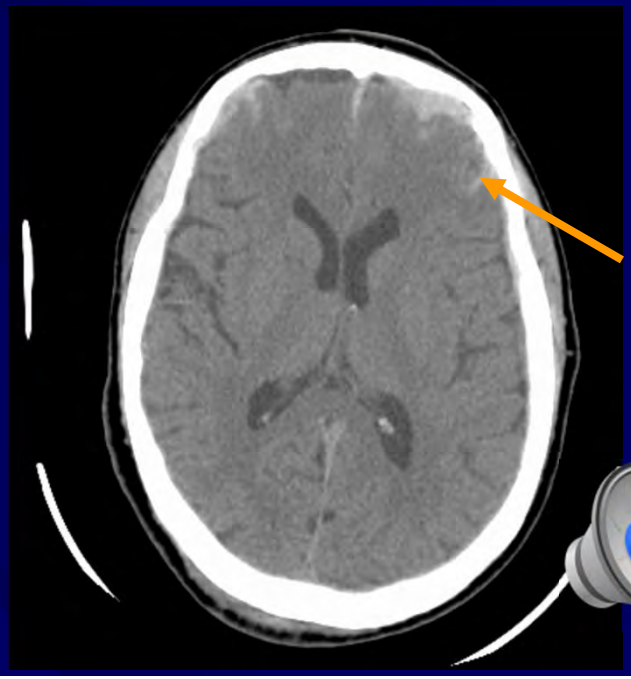

Idosa sem história de queda
Hemiparésia direita

Vitima de acidente de viação

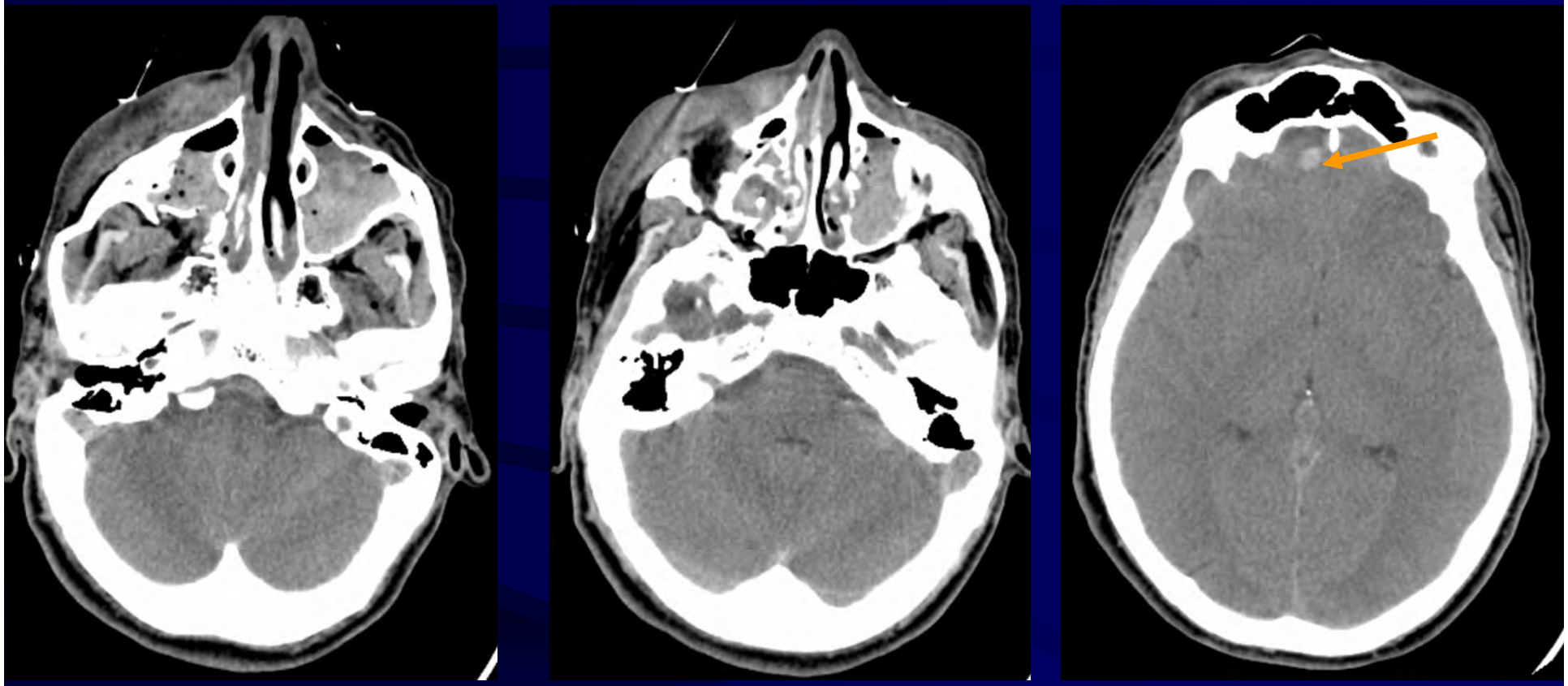

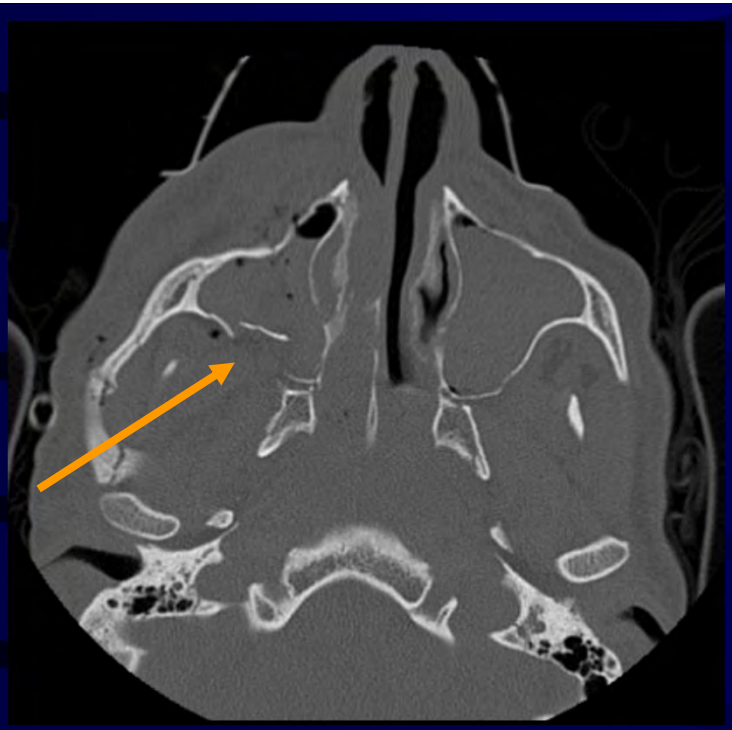

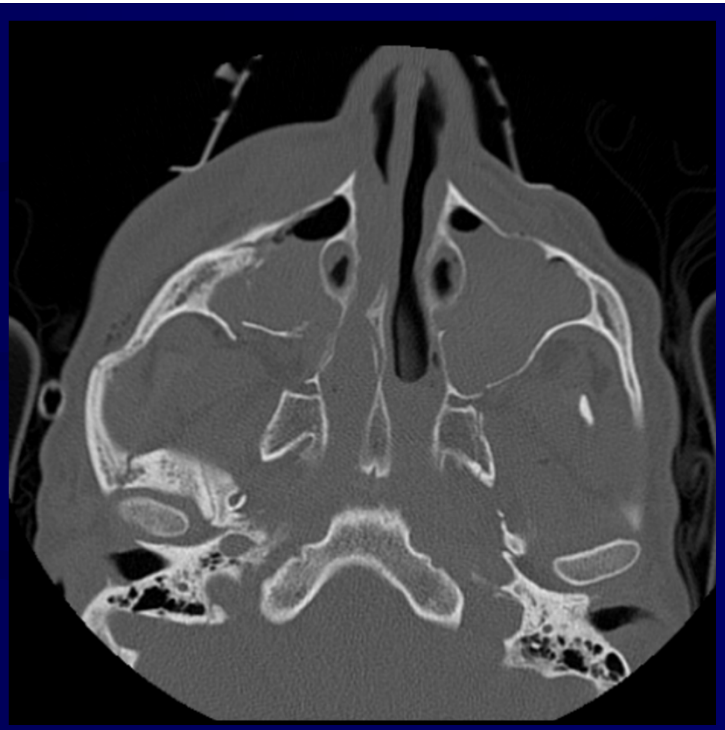

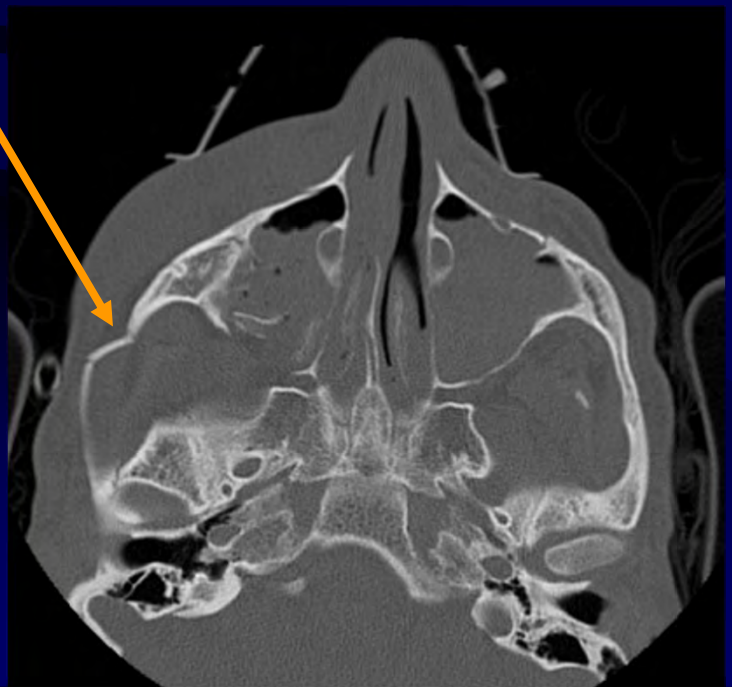

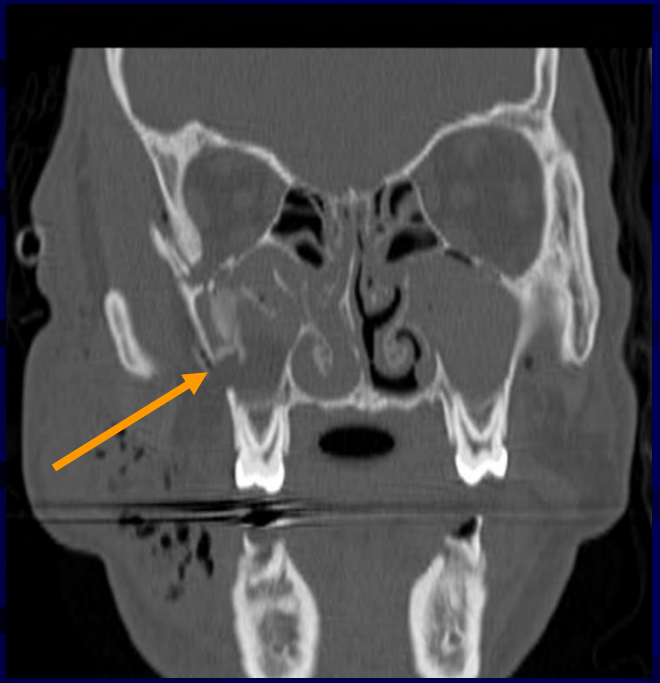

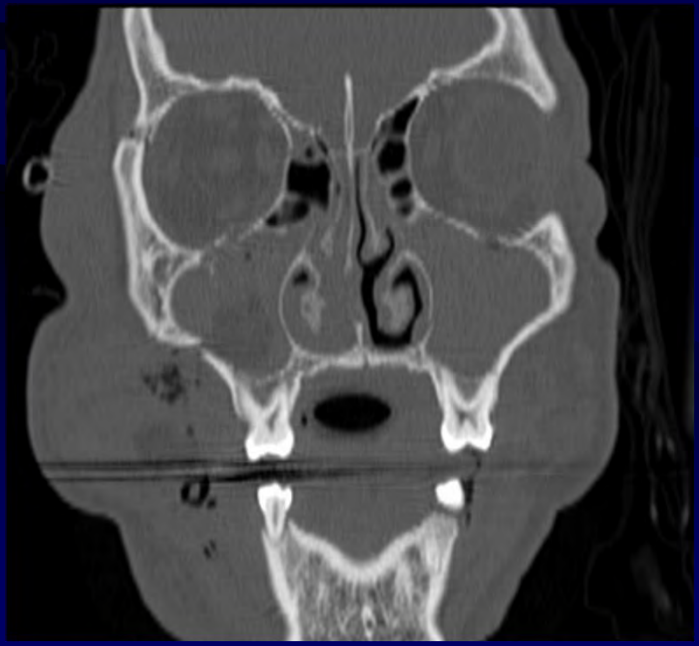

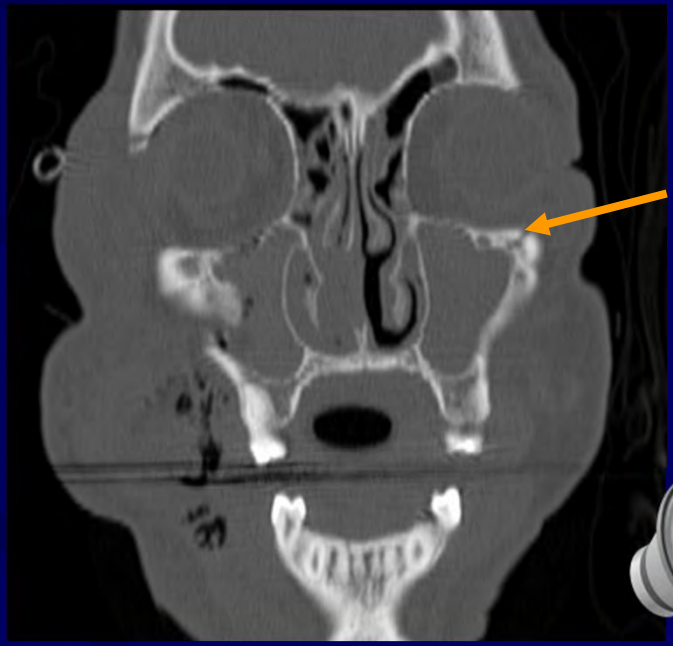

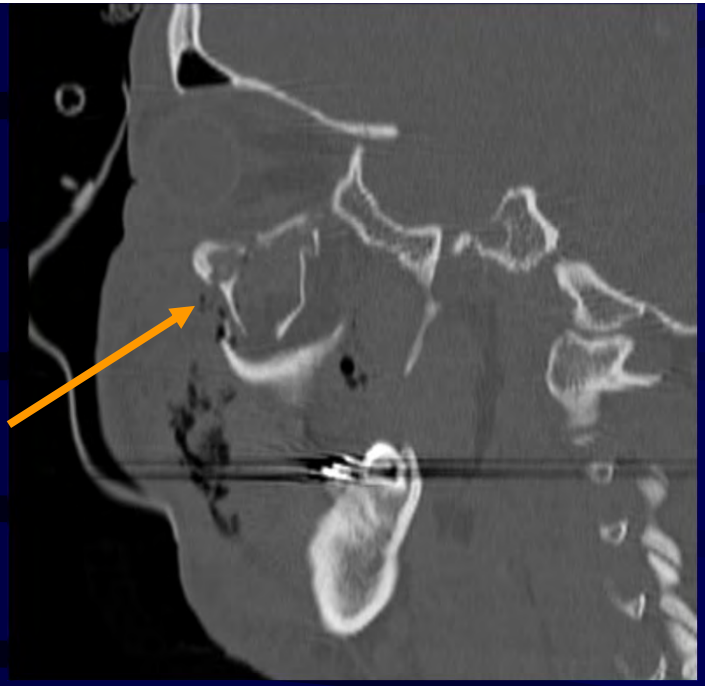

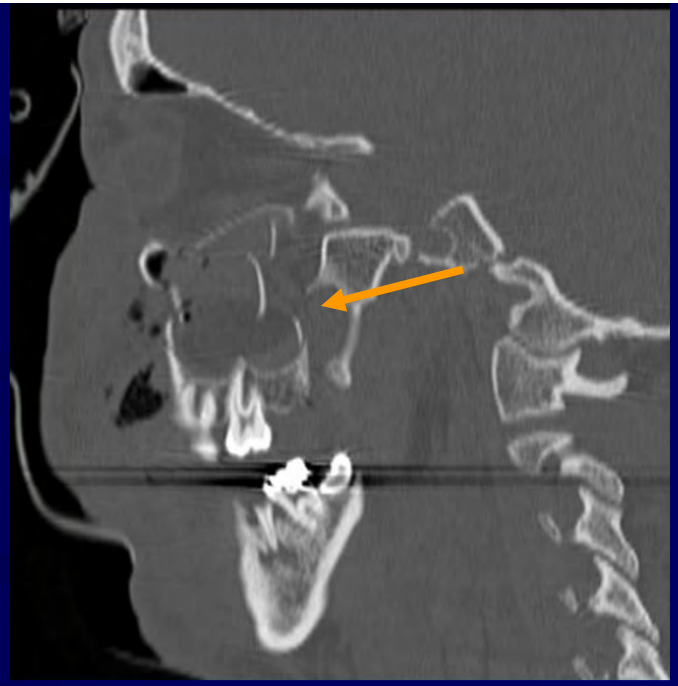

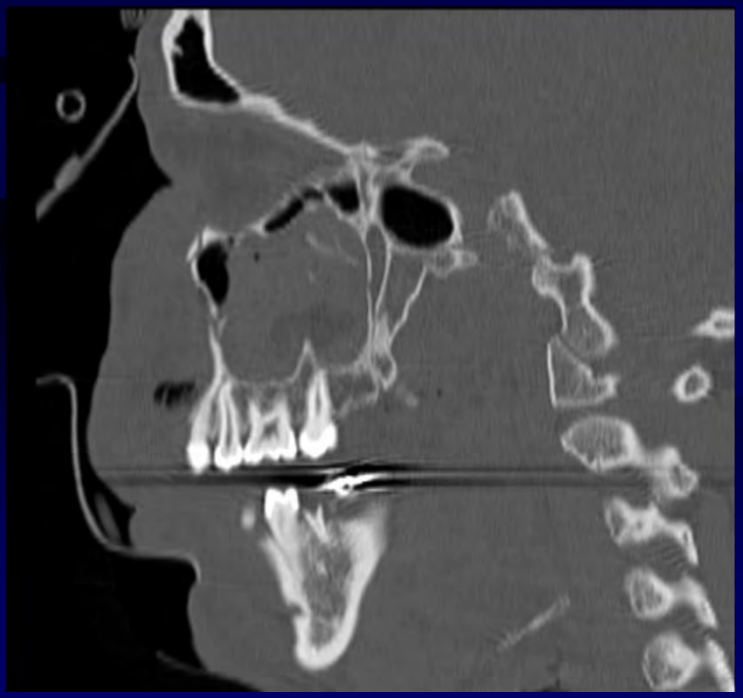

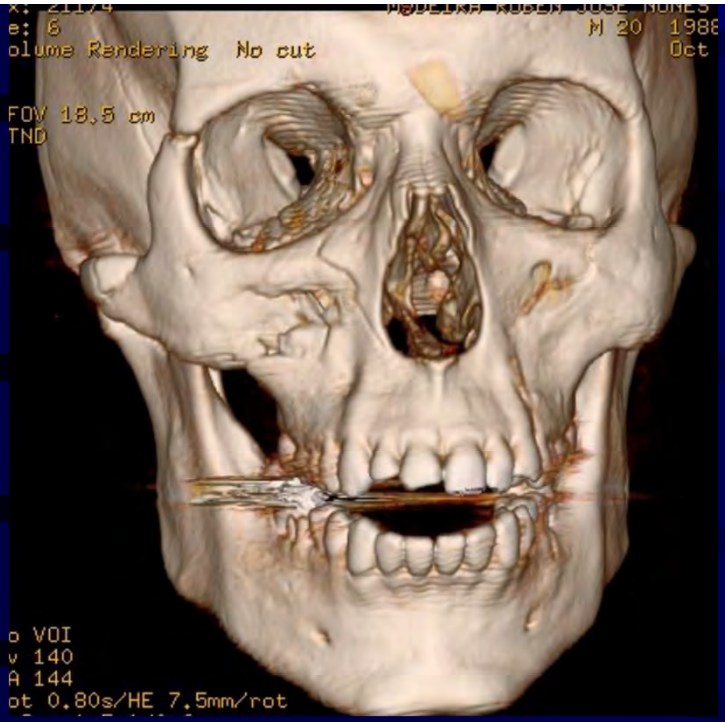
olume Rendering No cut
FOV 18.5 cm
TND
o VOI
v 140
A 144
ot 0.80s/HE 7.5mm/rot

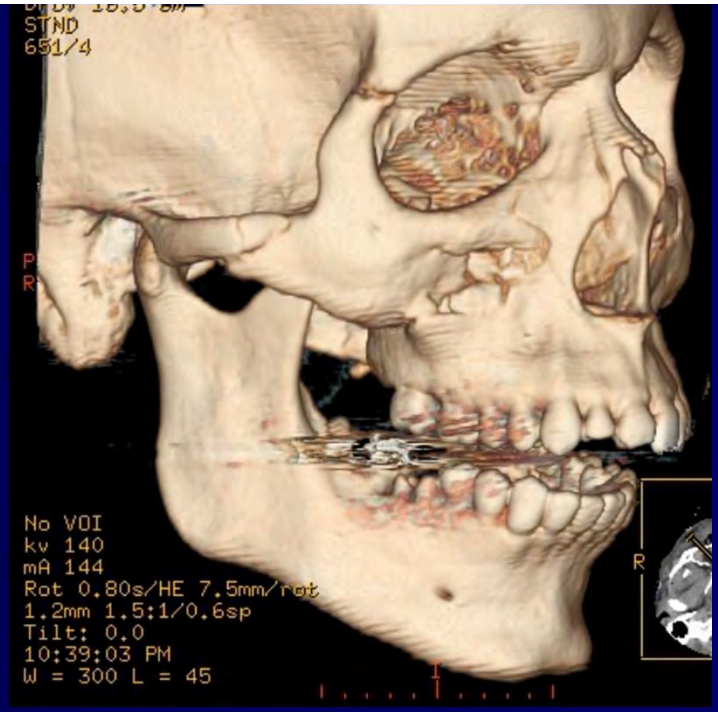
STND
651/4
No VOI
kv 140
mA 144
Rot 0.80s/HE 7.5mm/rot
1.2mm 1.5:1/0.6sp
Tilt: 0.0
10:39:03 PM
W = 300 L = 45
R

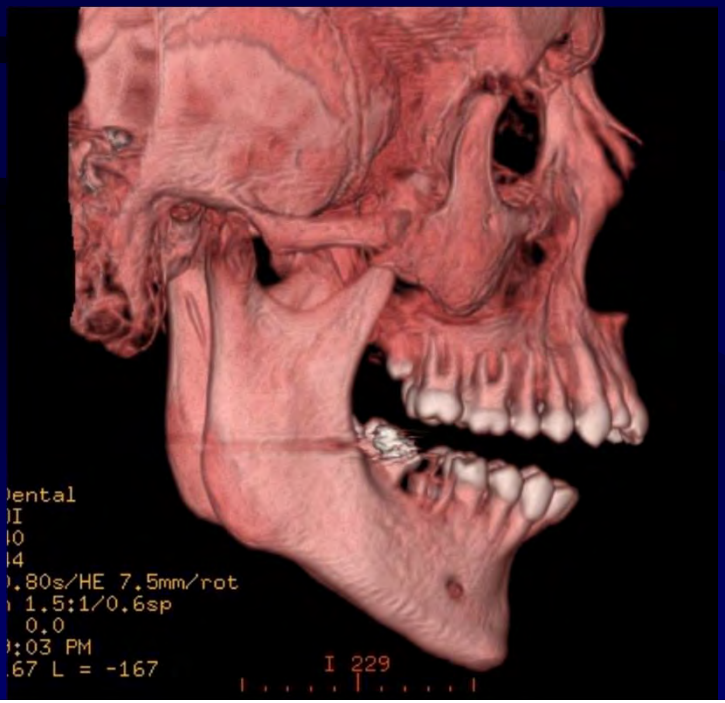
.80s/HE 7.5mm/rot
1.5:1/0.6sp
0.0
:03 PM
67 L = -167
I 229

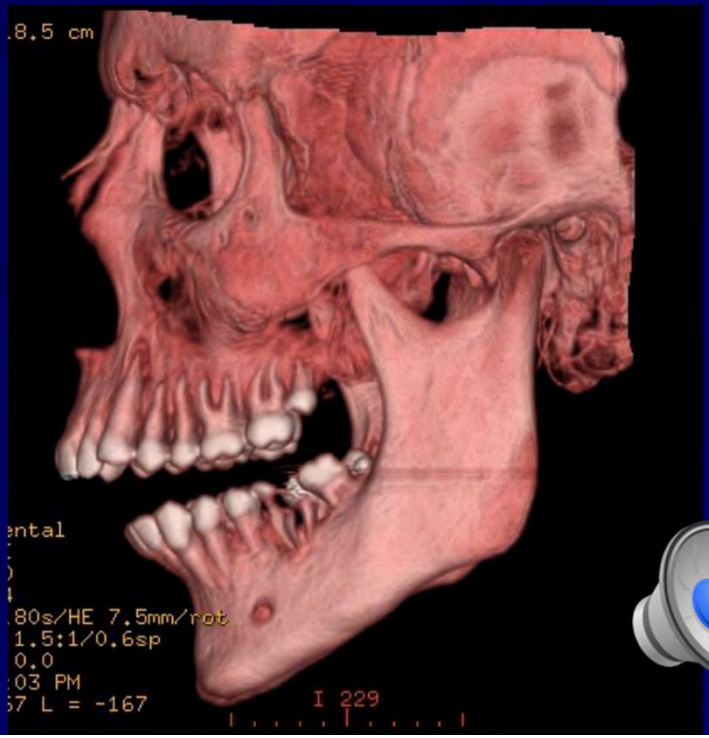
8.5 cm
ental
80s/HE 7.5mm/rot
1.5:1/0.6sp
0.0
03 PM
7 L = -167
I 229

Traumatismo vertebro-medular

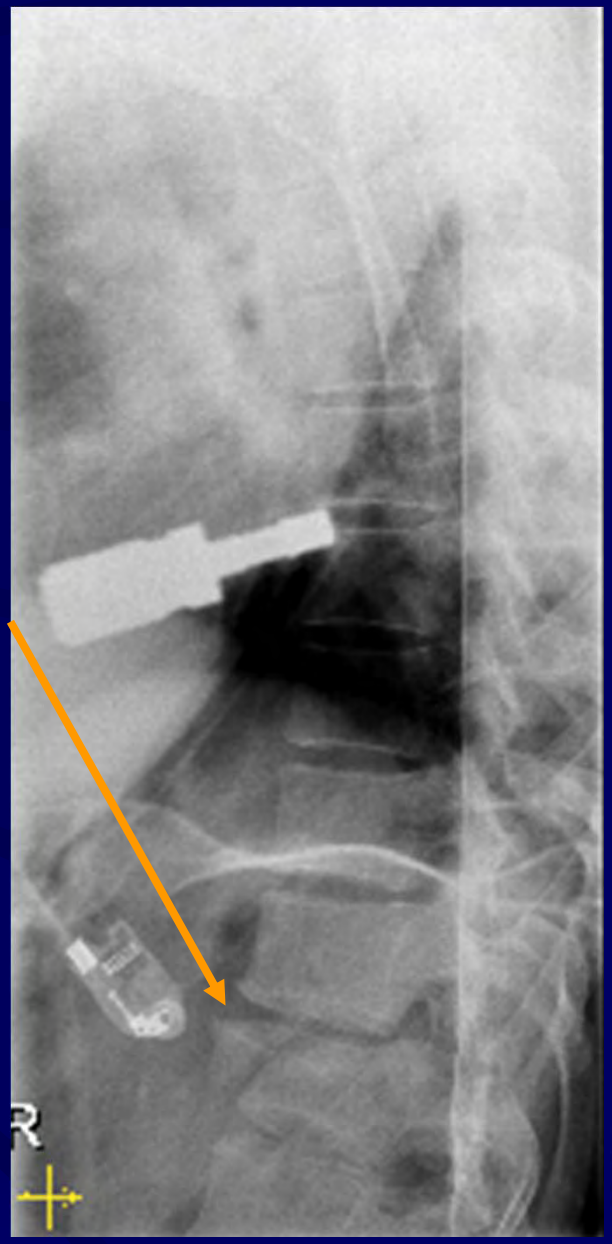

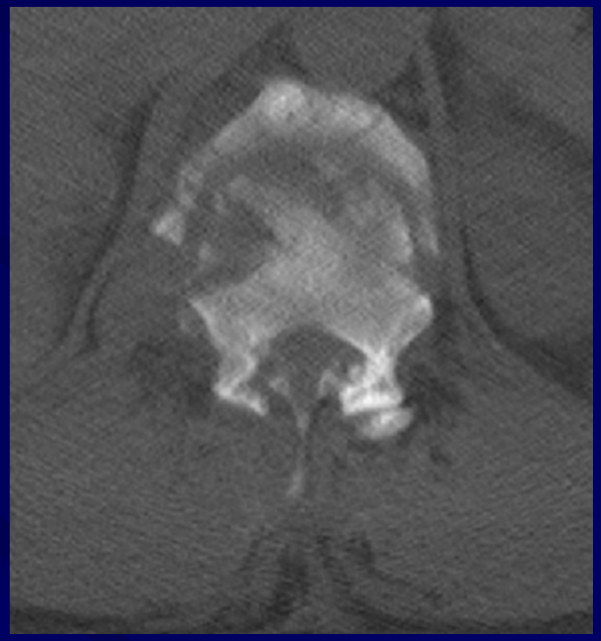

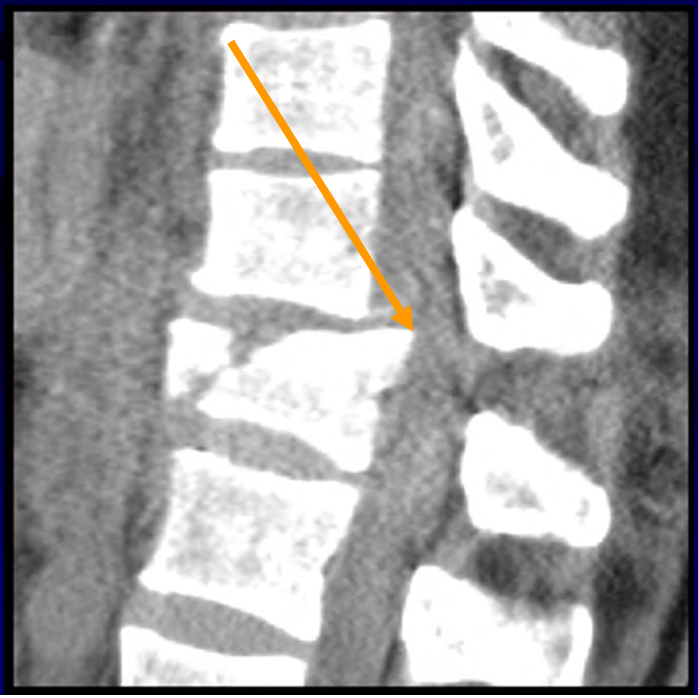

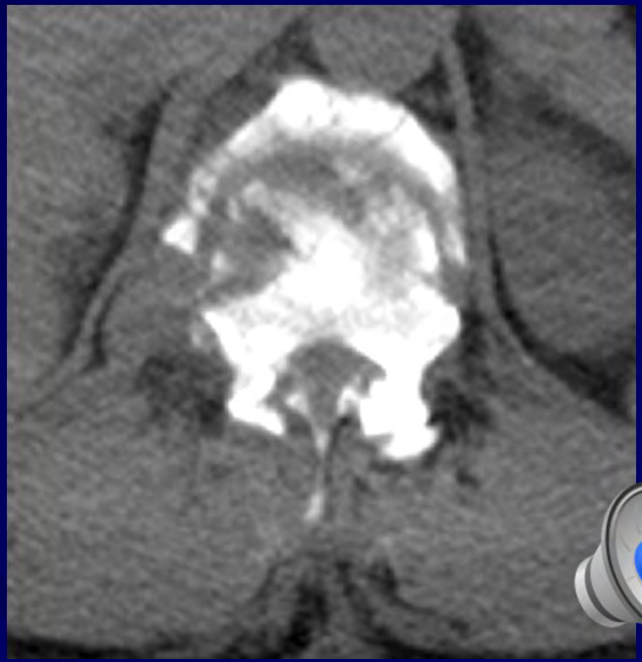

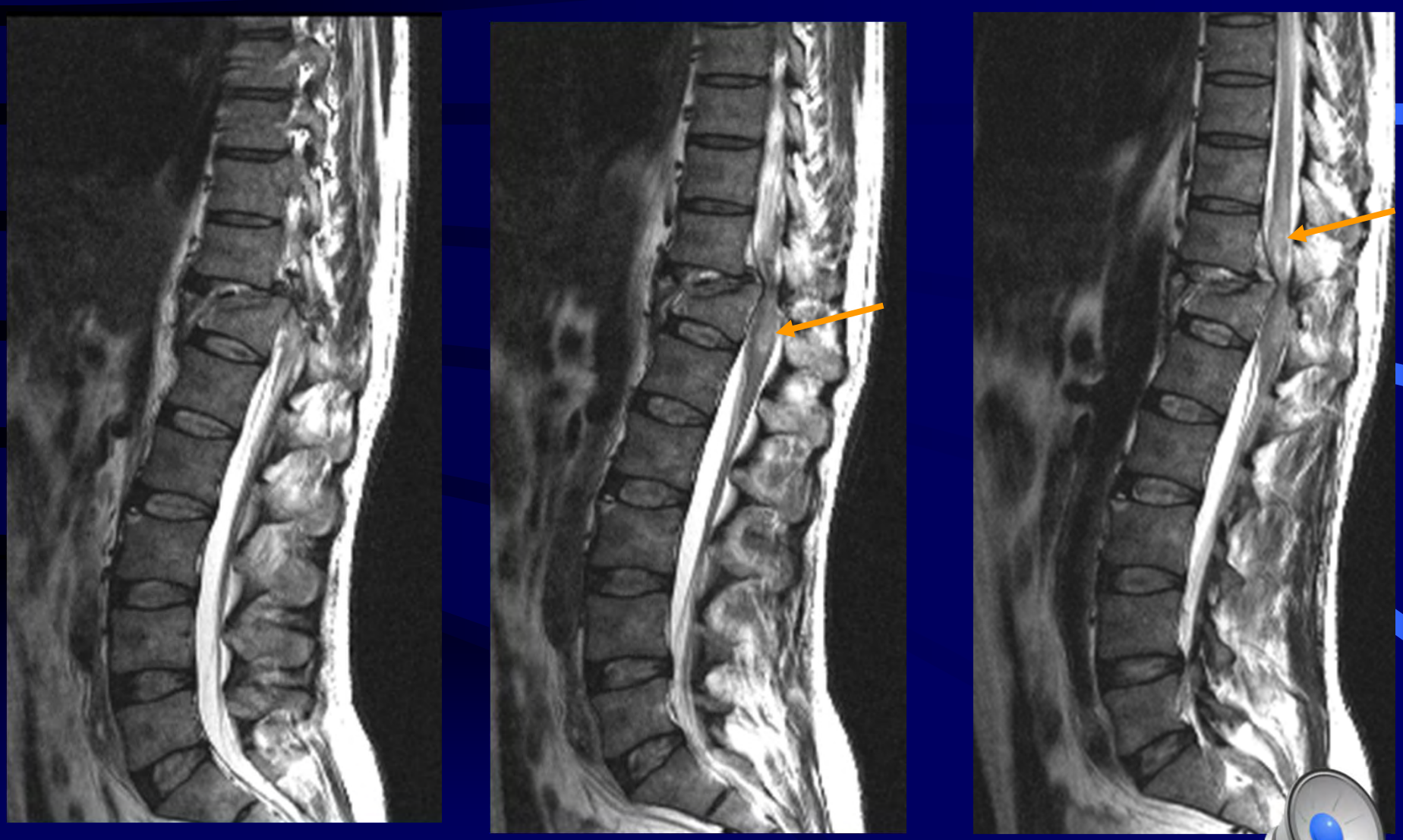

PATOLOGIA DEGENERATIVA OSTEO-DISCAL

TC - exame de 1ª linha na avaliação osteo-discal

RM - detecção precoce das alterações degenerativas
- melhor caracterização das alterações discais
- avaliação pós-cirurgica

Lombociatalgia esquerda

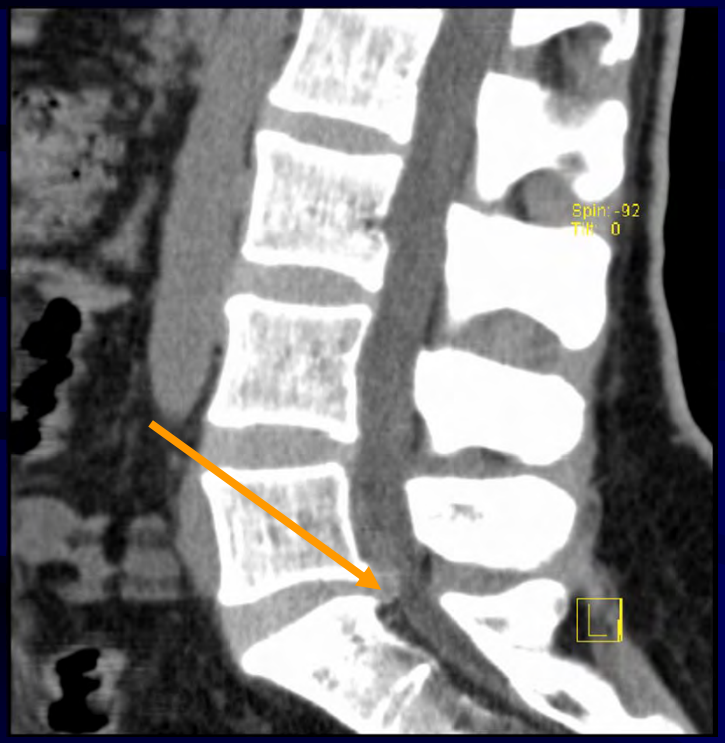

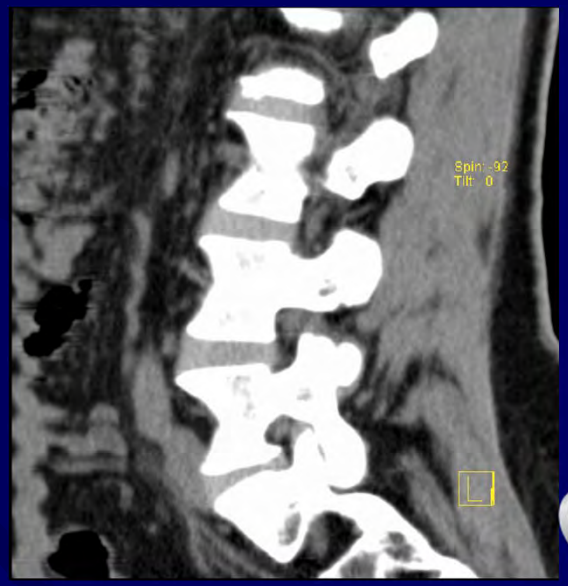

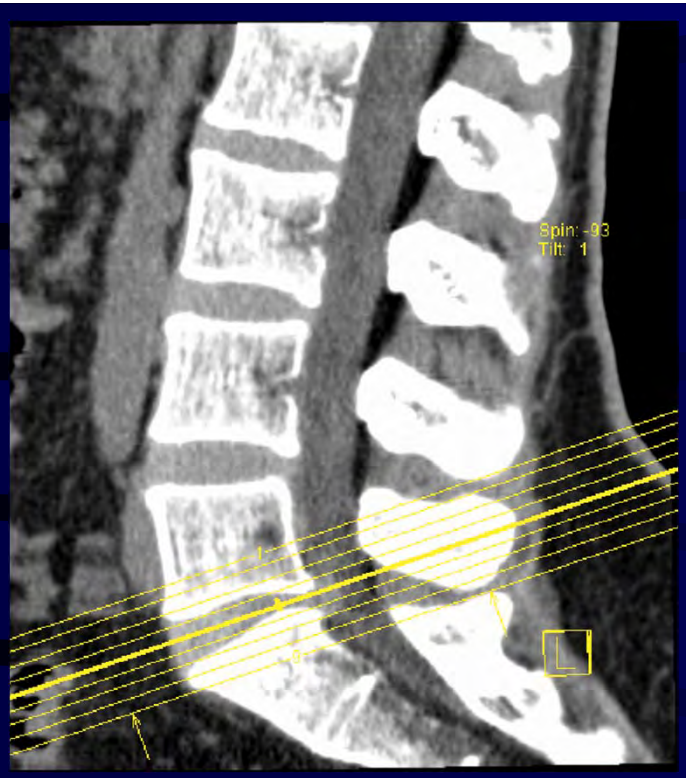
Spin: -93
Tilt: 1

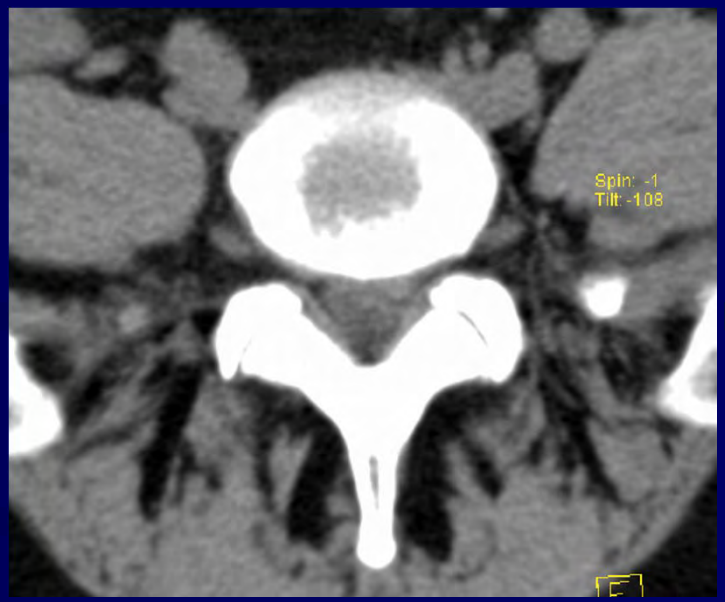
Spin: -1
Tilt: -108

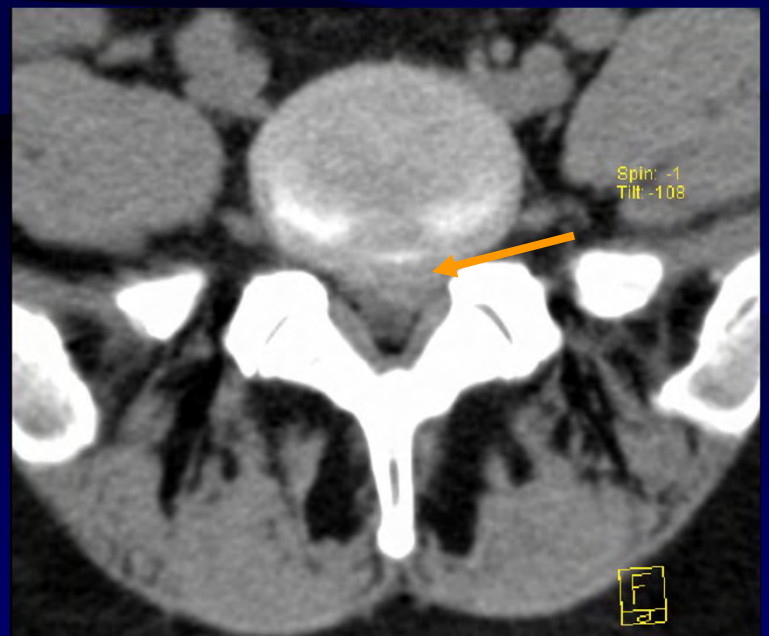
Spin: -1
Tilt: -108

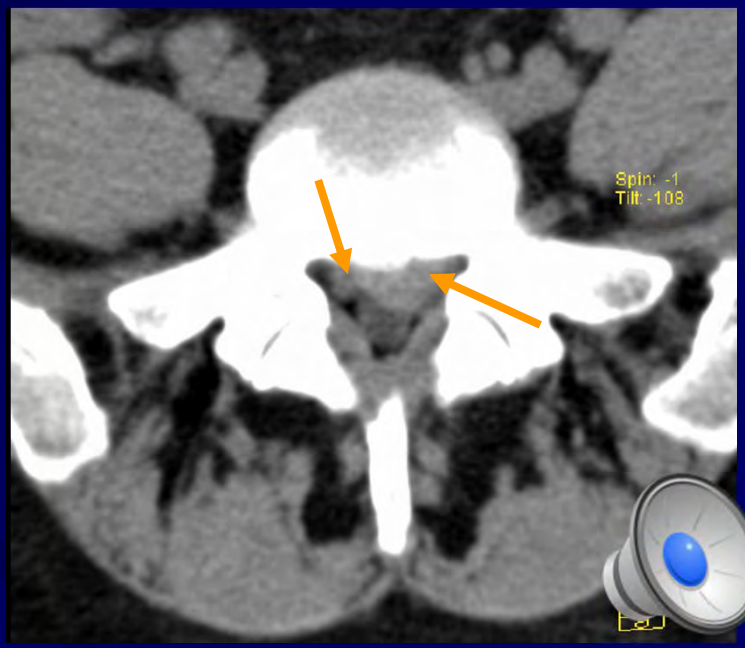
Spin: -1
Tilt: -108

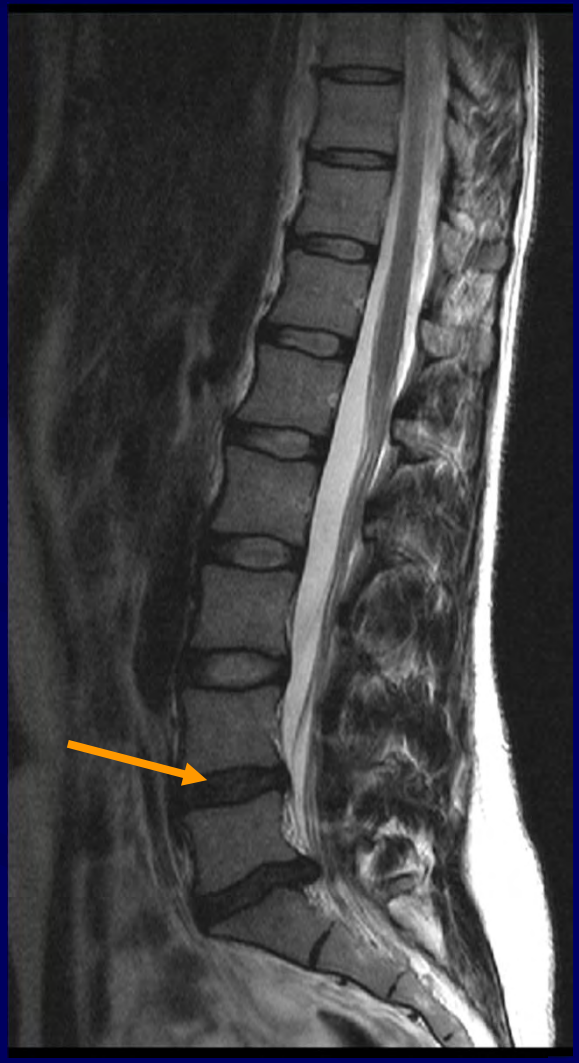

Cervicobraquialgia esquerda

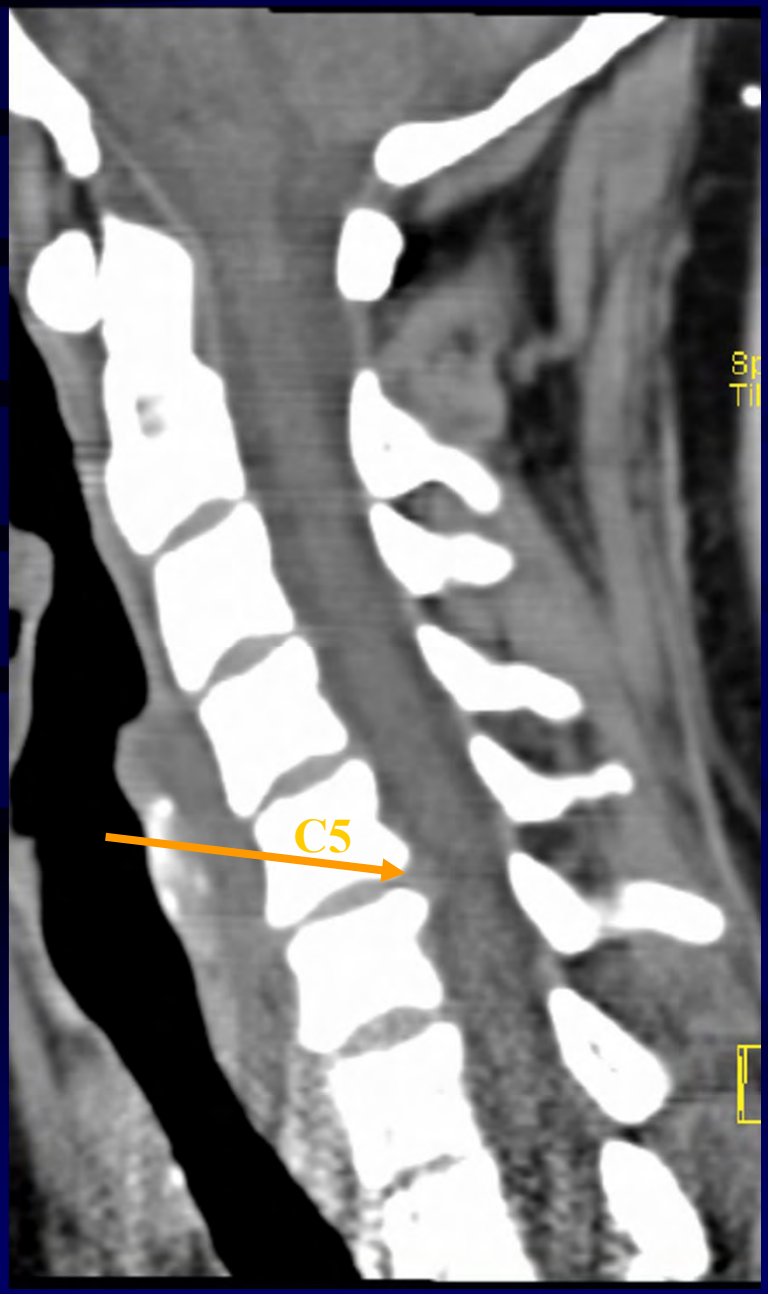

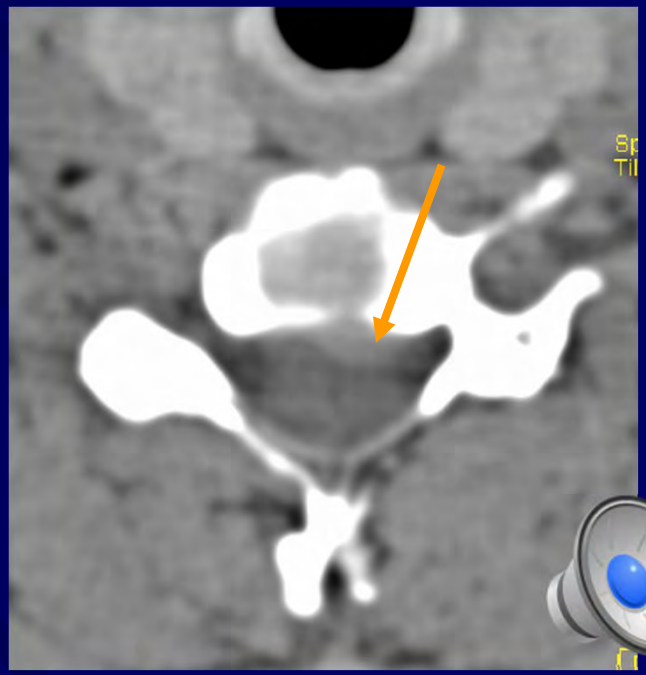

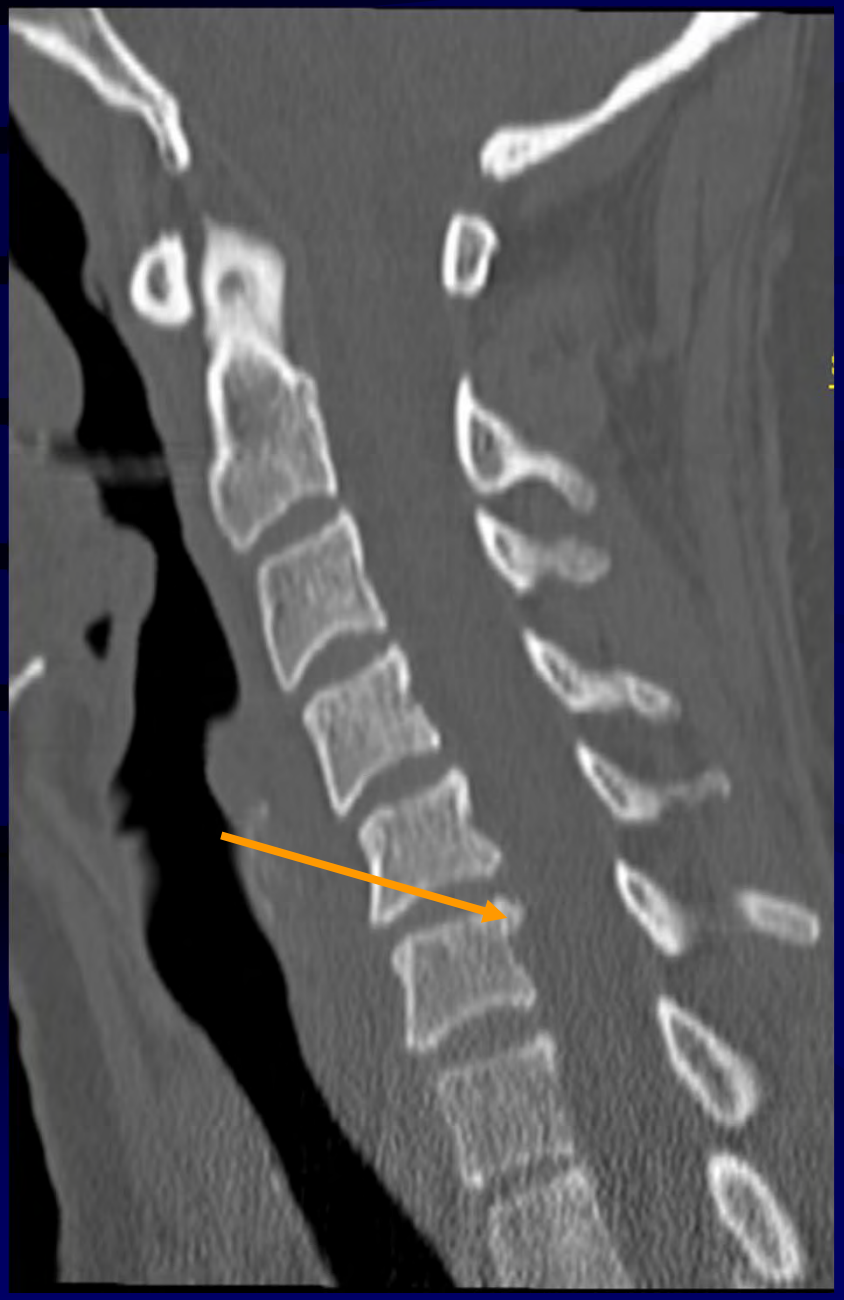

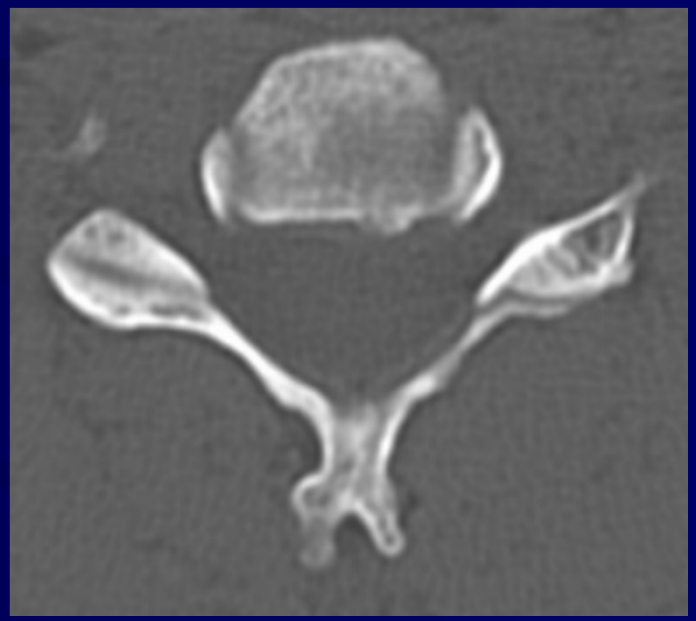

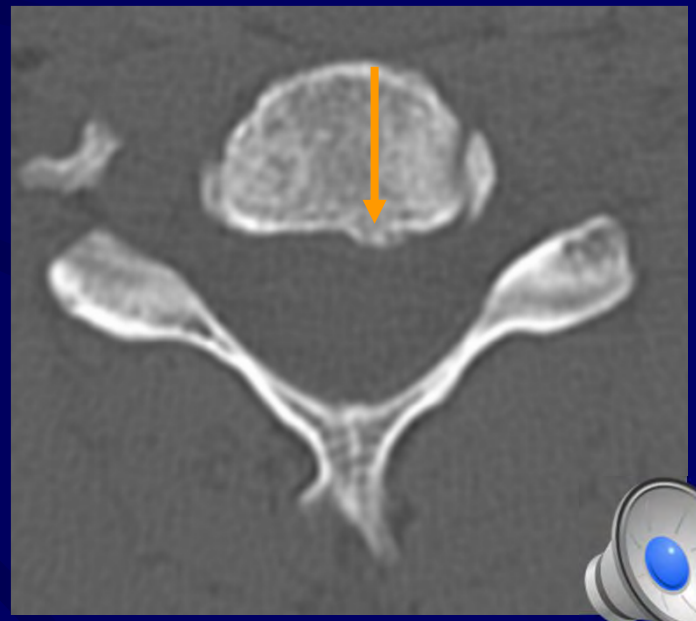

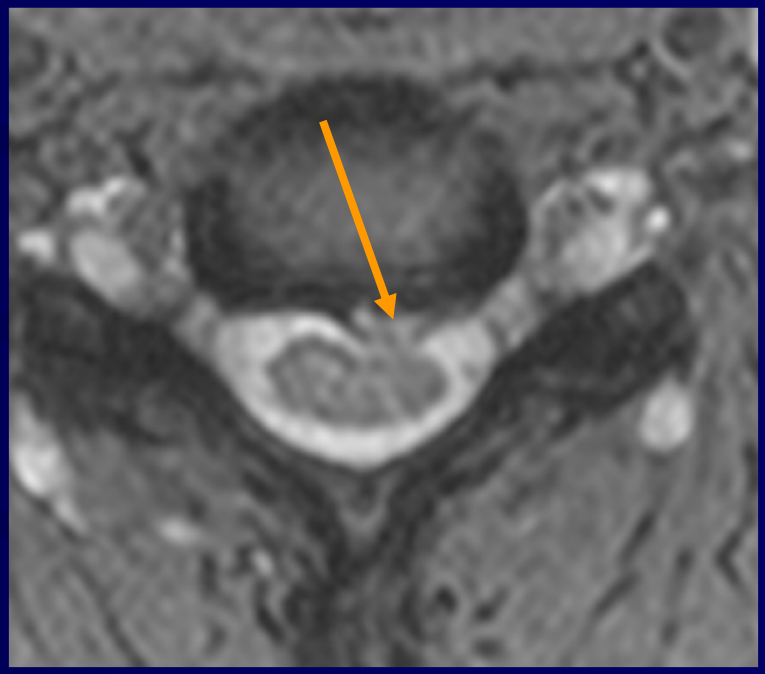

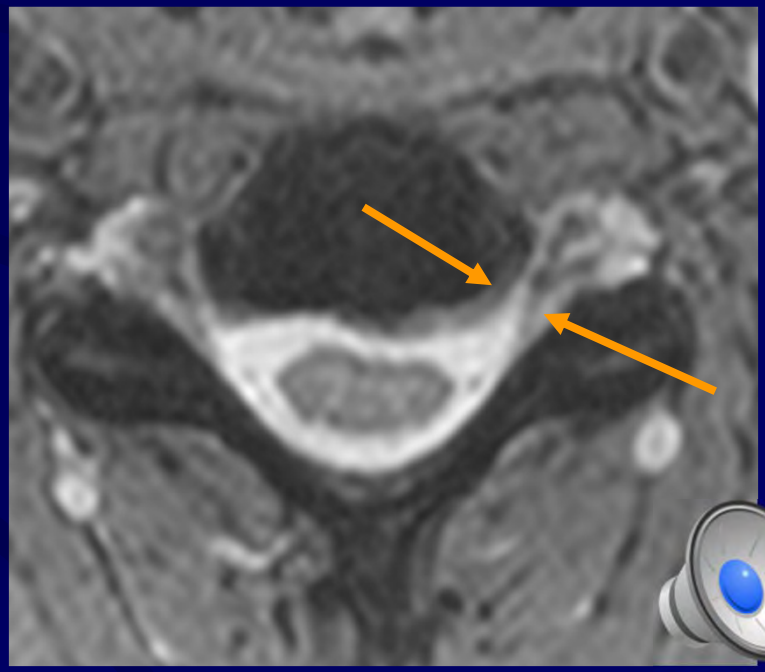

PATOLOGIA TUMORAL

TC e RM são complementares

TC - exame de 1ª linha
- caracterização das alterações ósseas

RM - detecção precoce das lesões dos tecidos moles e da infiltração óssea
- melhor caracterização das alterações teciduais
- Técnicas especiais
  - difusão e perfusão
  - espectroscopia

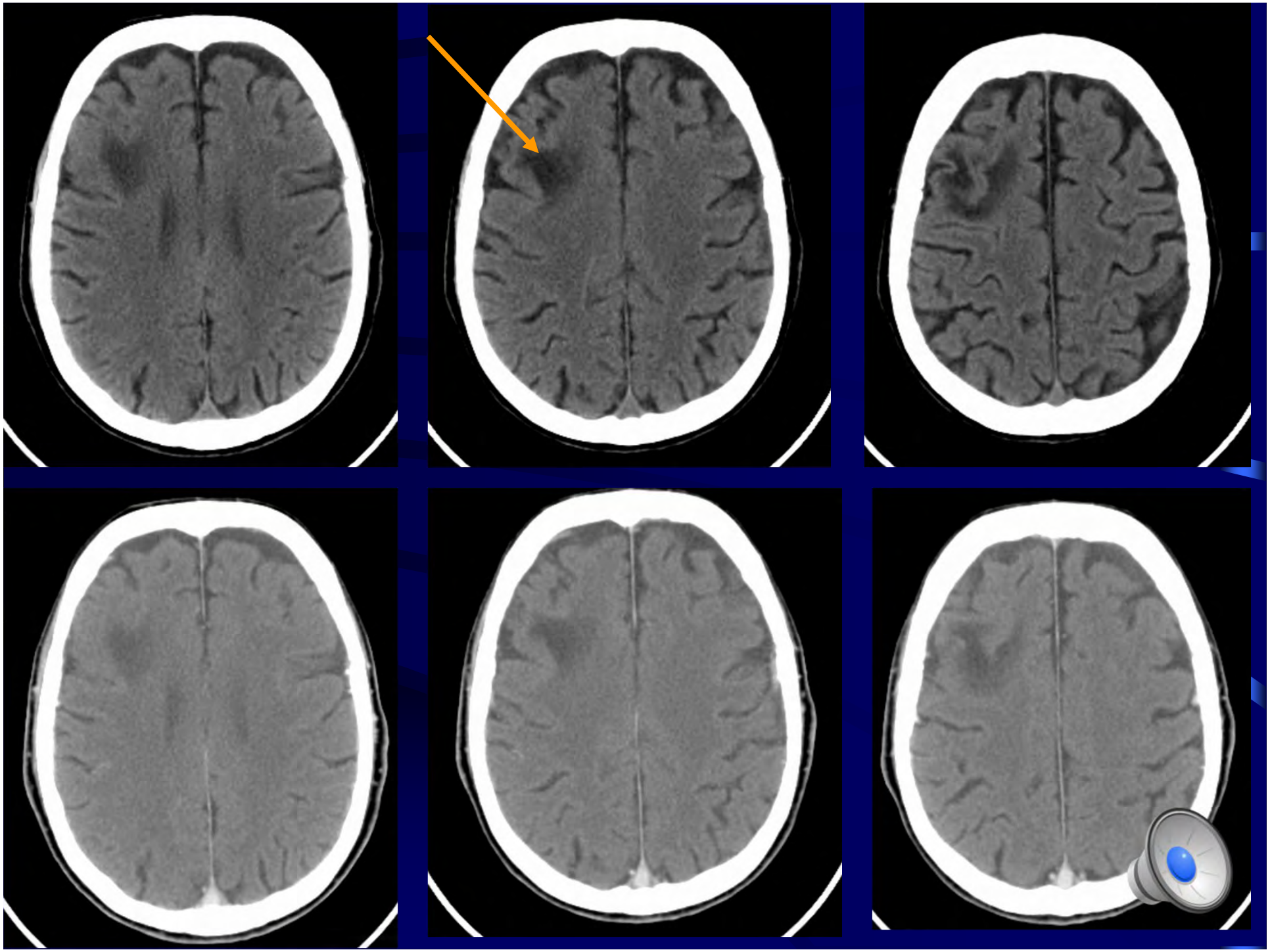

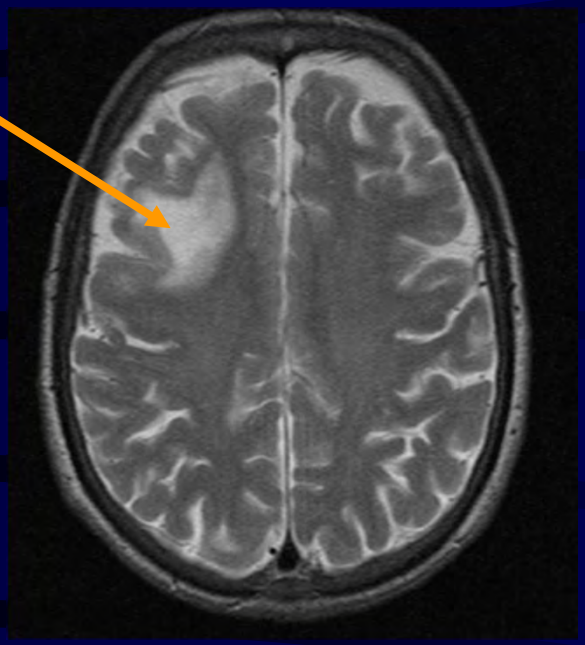

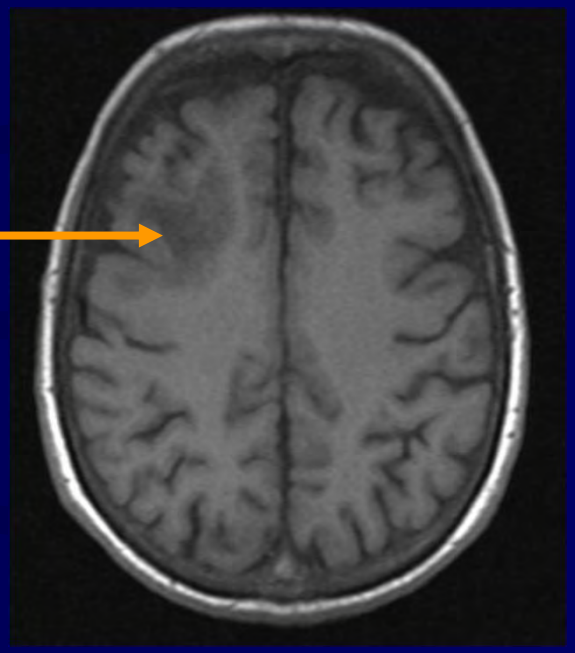

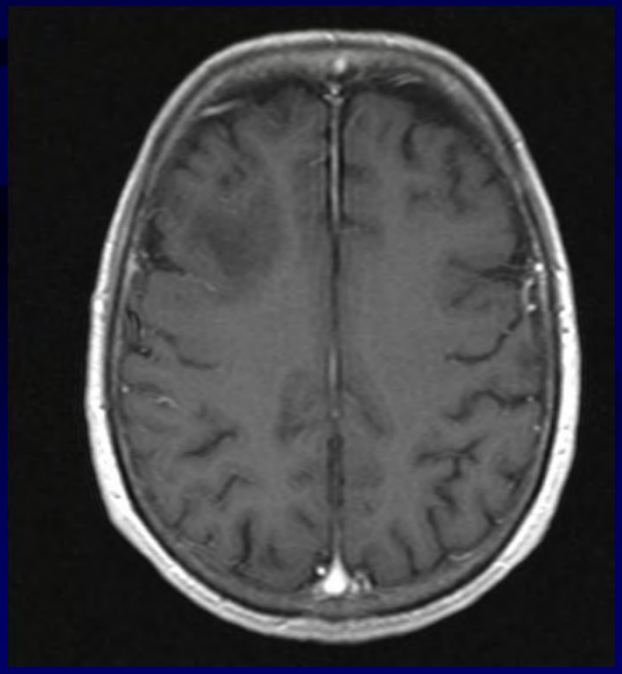

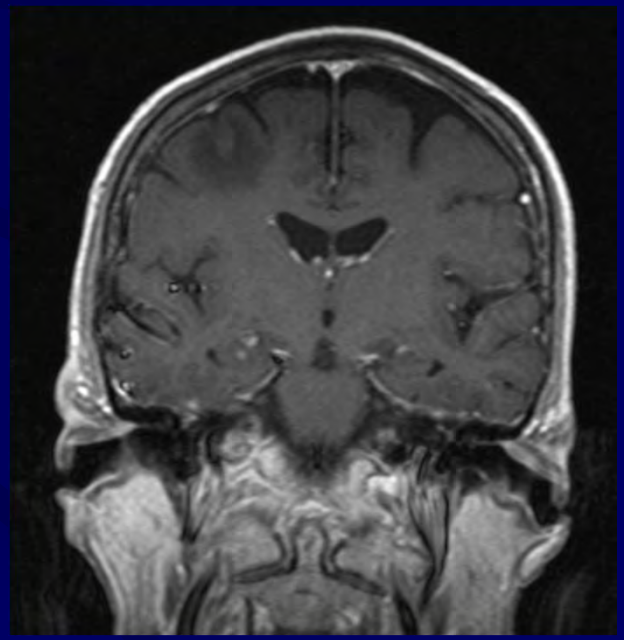

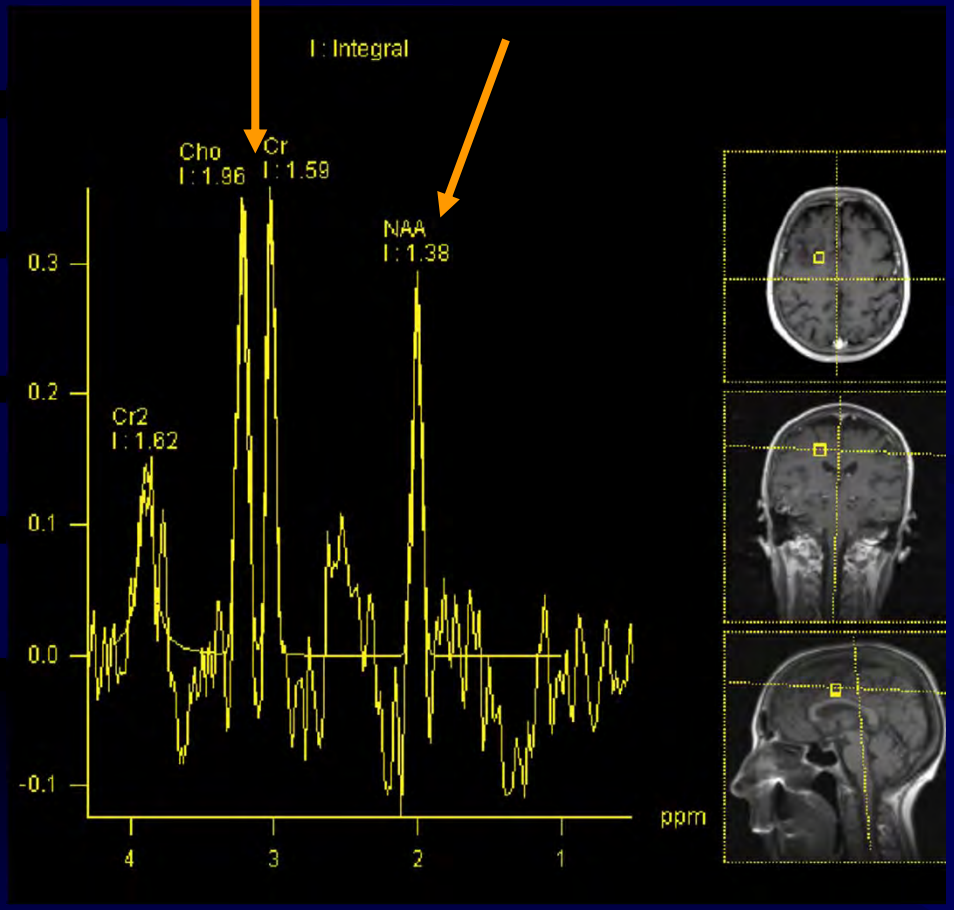
I : Integral
Cho
I : 1.96
Cr
I : 1.59
NAA
I : 1.38
Cr2
I : 1.62
0.3
0.2
0.1
0.0
-0.1
4
3
2
1
ppm

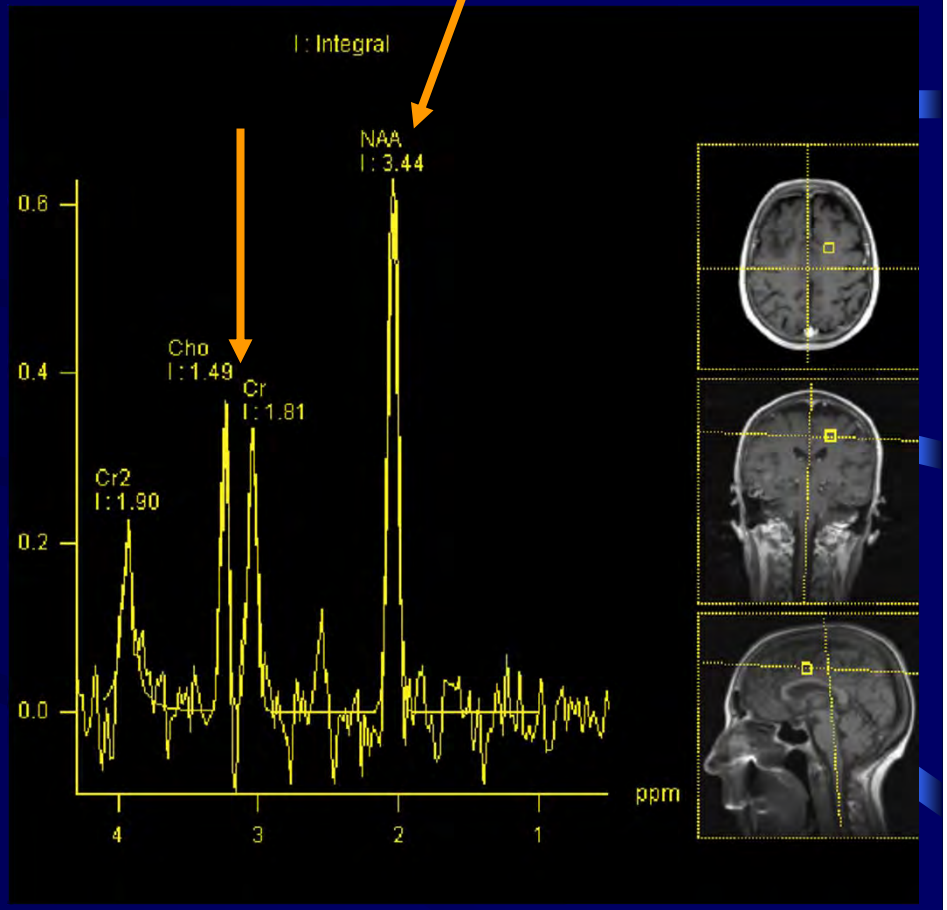
I : Integral
NAA
I : 3.44
Cho
I : 1.49
Cr
I : 1.81
Cr2
I : 1.90
0.6
0.4
0.2
0.0
4
3
2
1
ppm

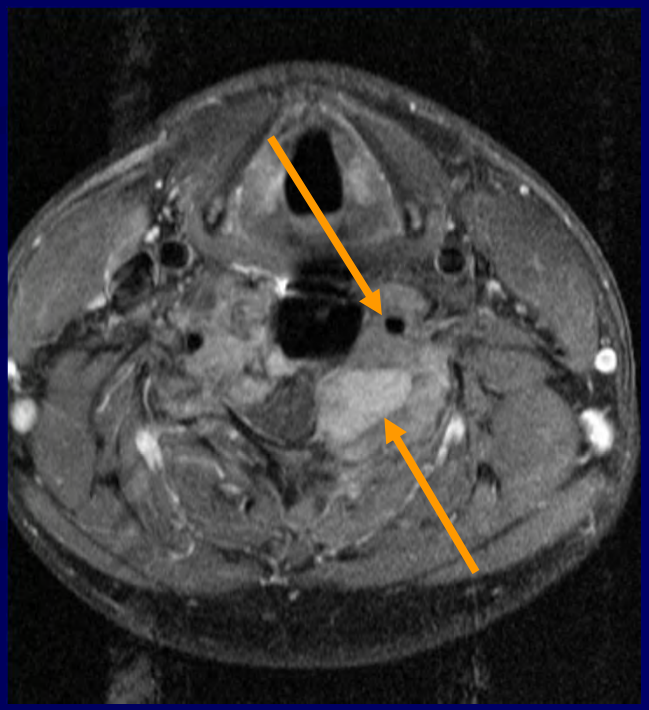

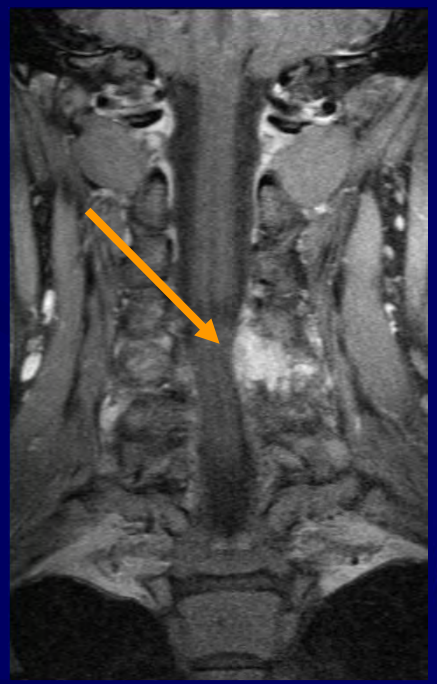

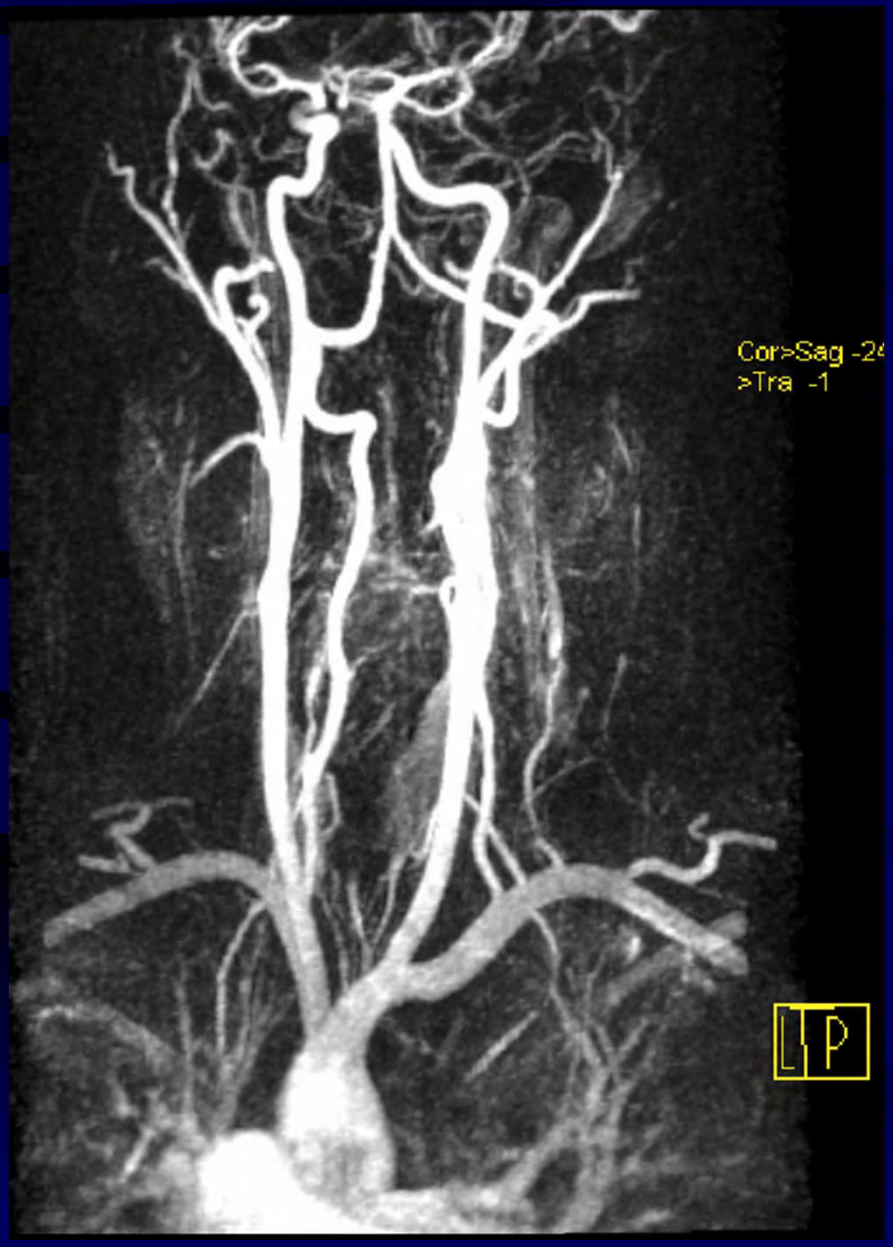
Cor>Sag -24
>Tra -1
L P

Cor>Sag 7
>Tra 4
P

Metástases

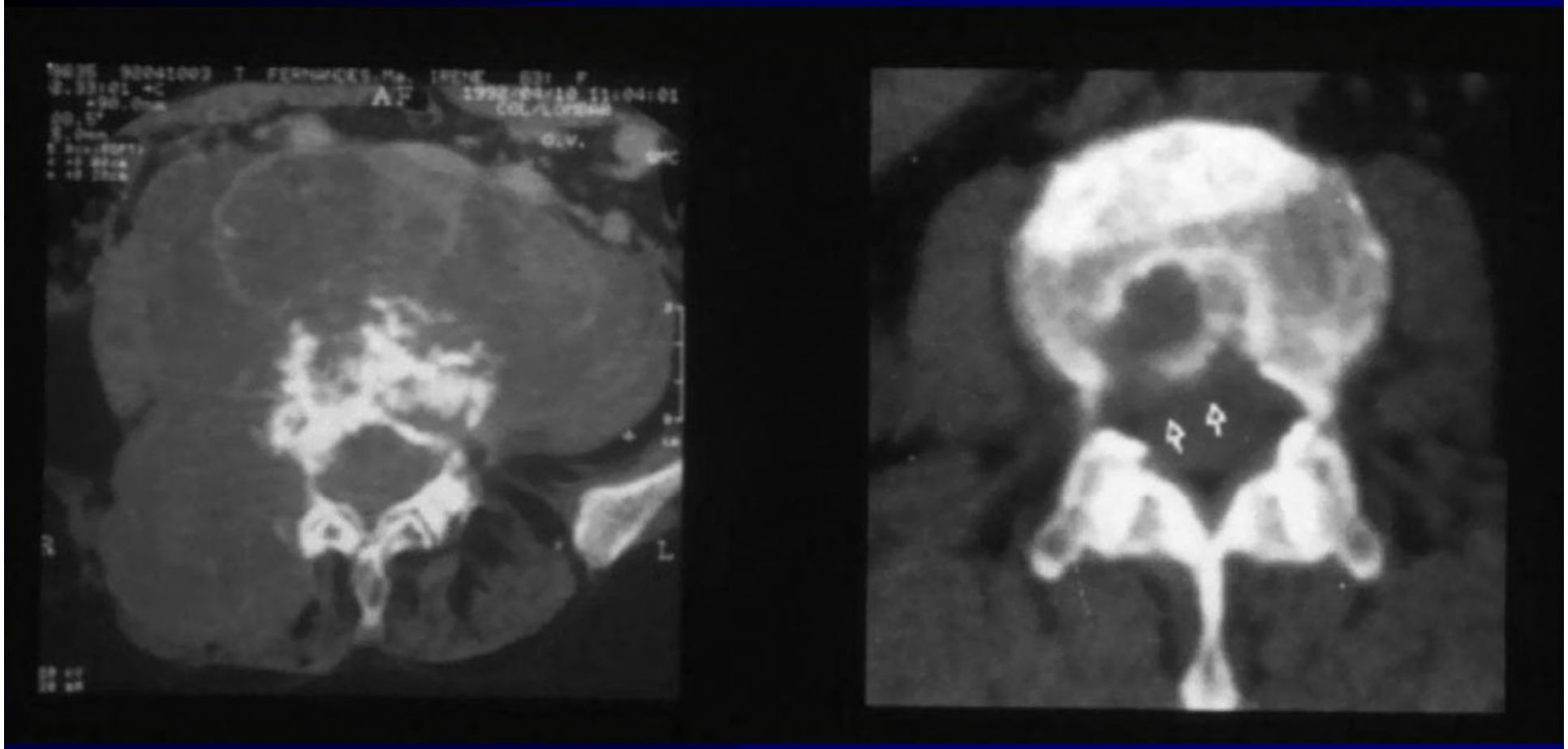

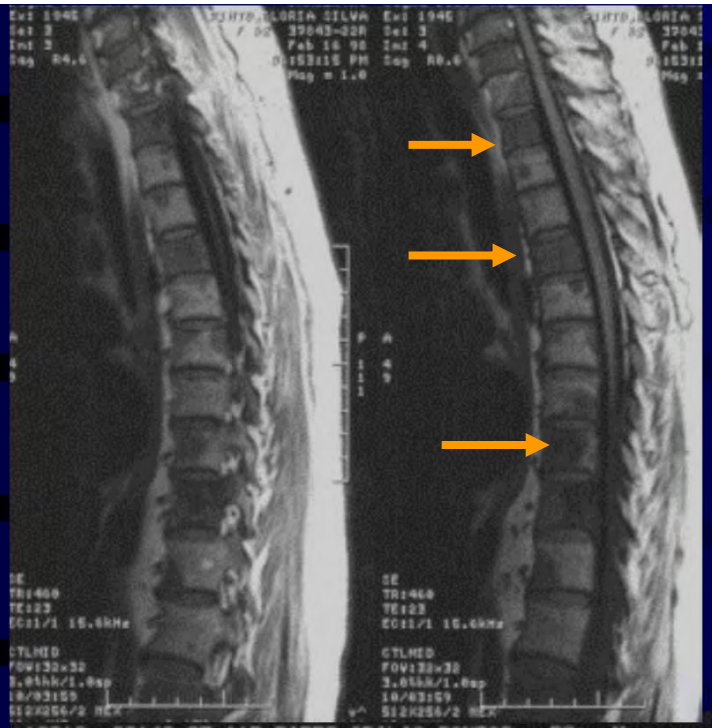

18612 29143.97-11R PIRES,ABILIO SANTOS 52: M
/SE

PATOLOGIA INFECCIOSA E INFLAMATÓRIA

TC e RM são complementares

♂ jovem

Febre
+
cefaleias

♂ meia-idade

desiq. súbito

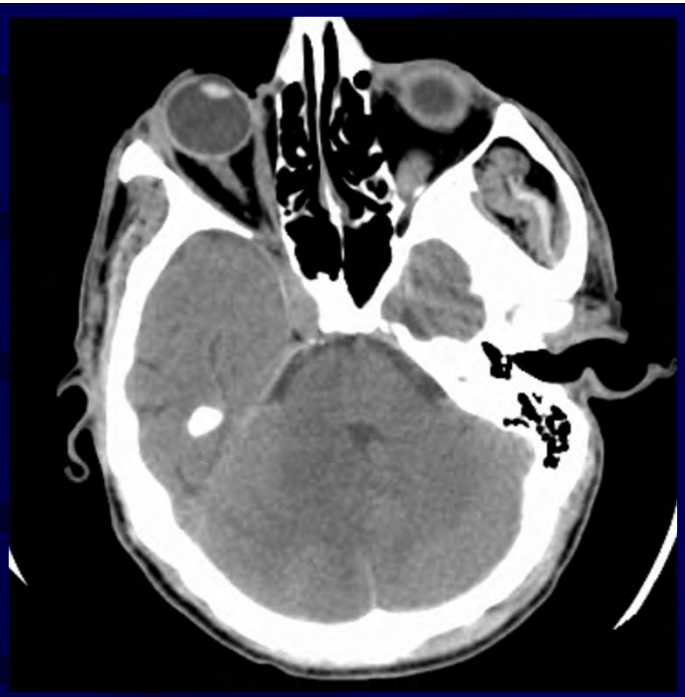

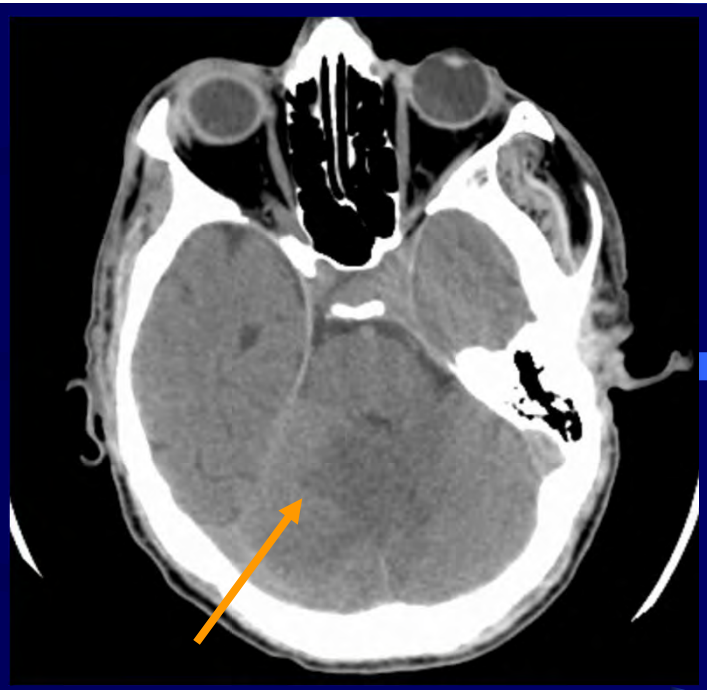

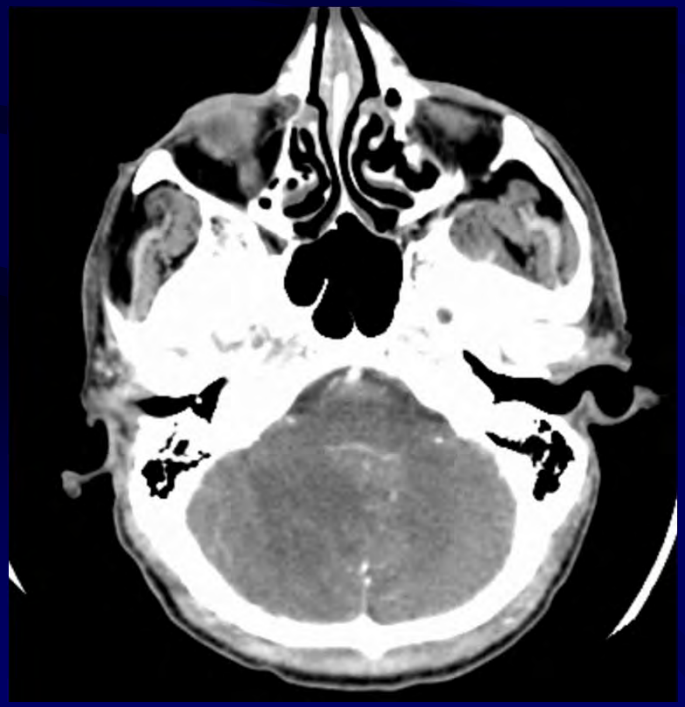

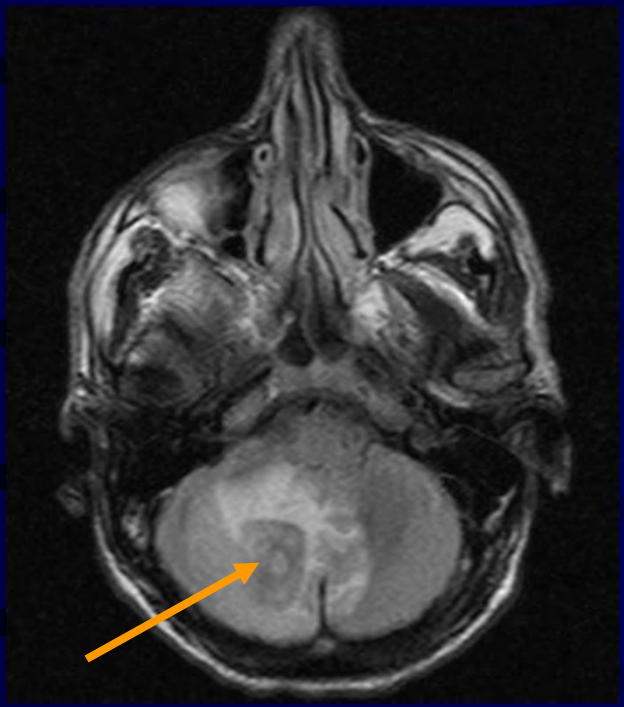

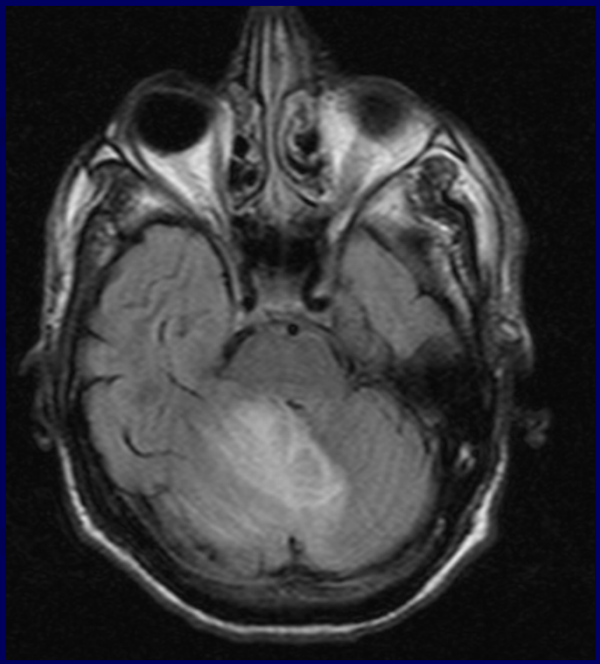

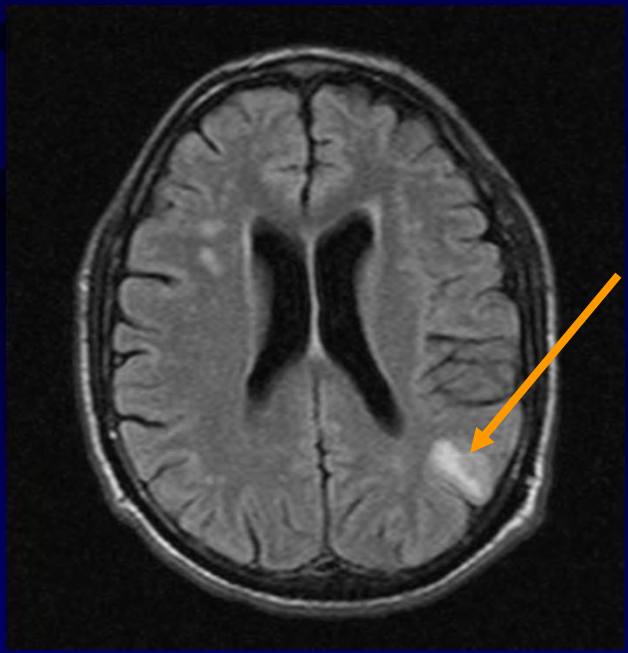

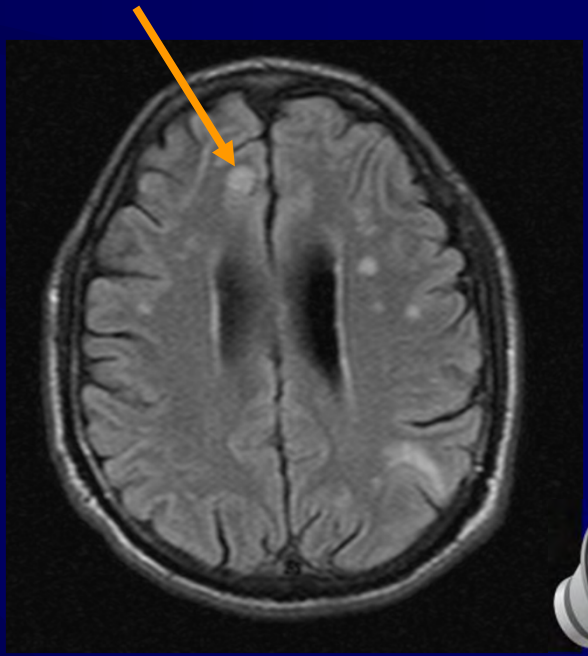

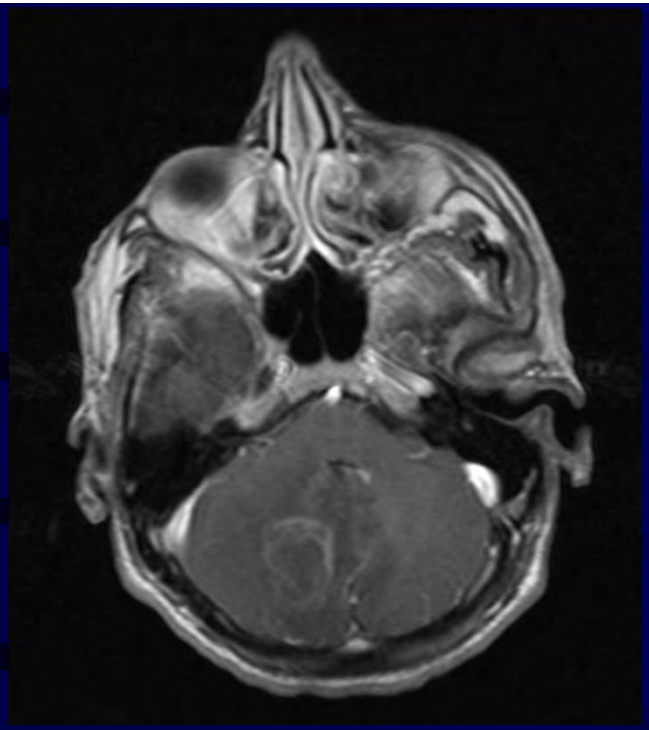

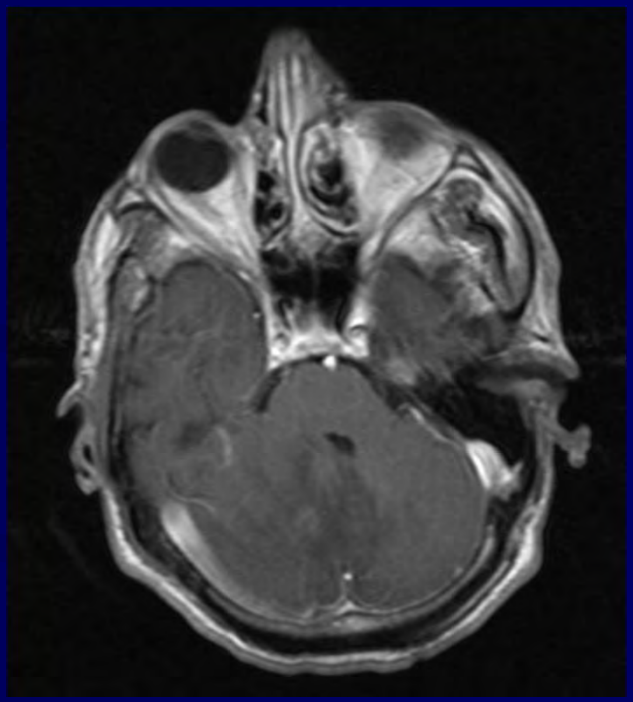

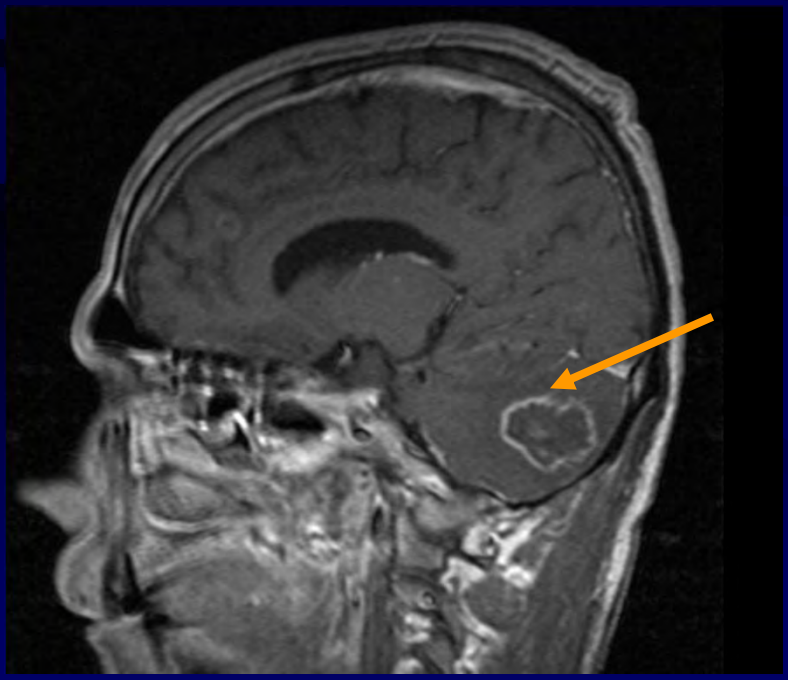

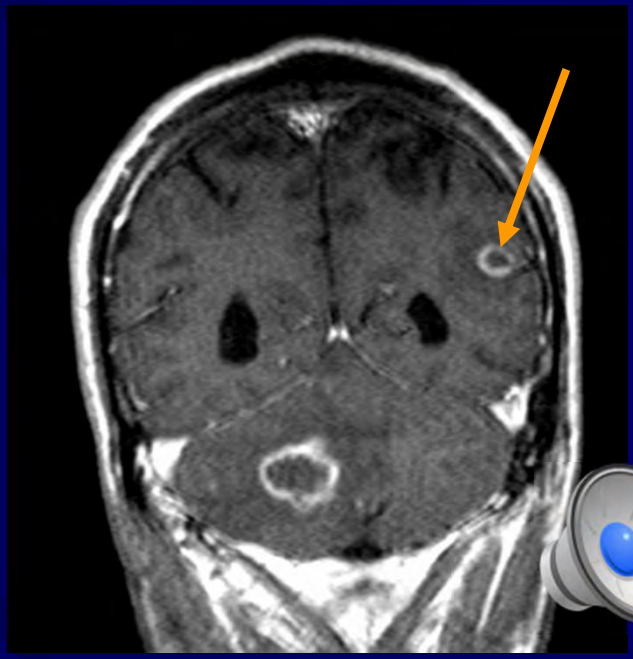

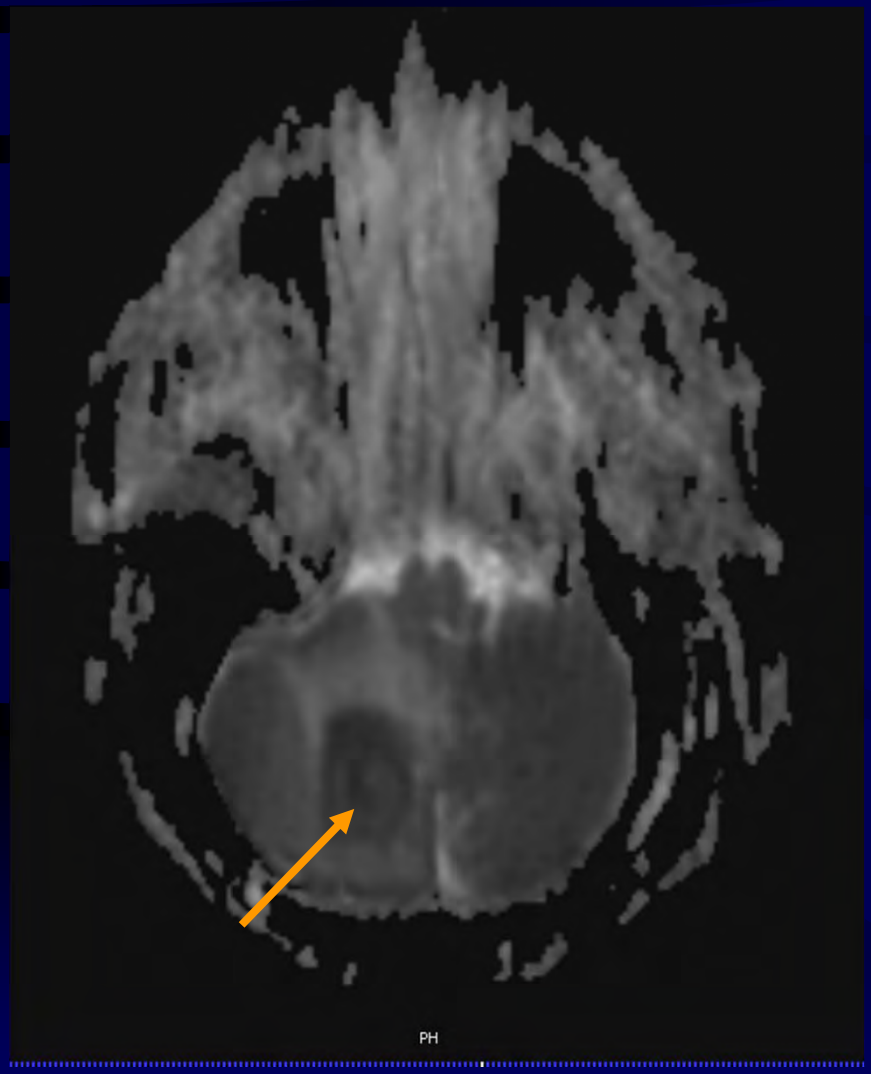
PH

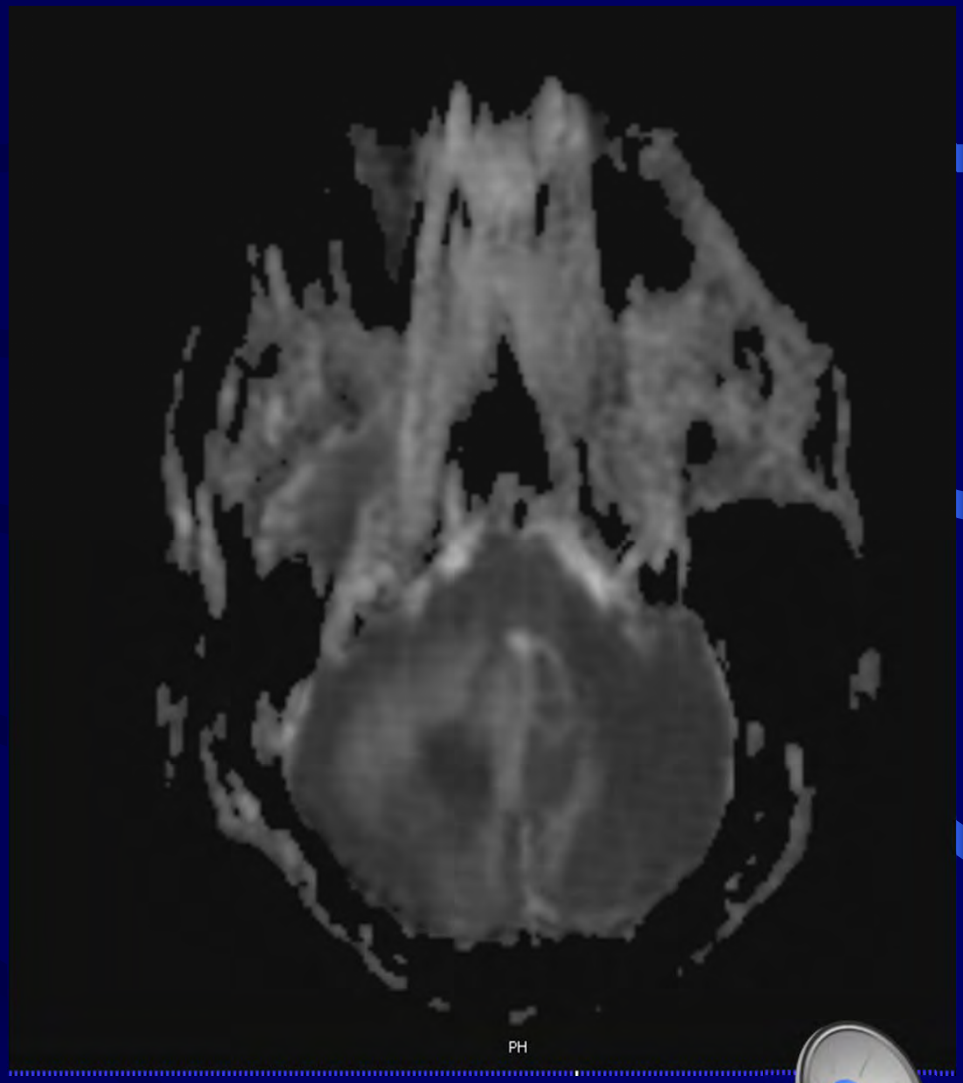
PH

♂ jovem

raça negra

convulsões

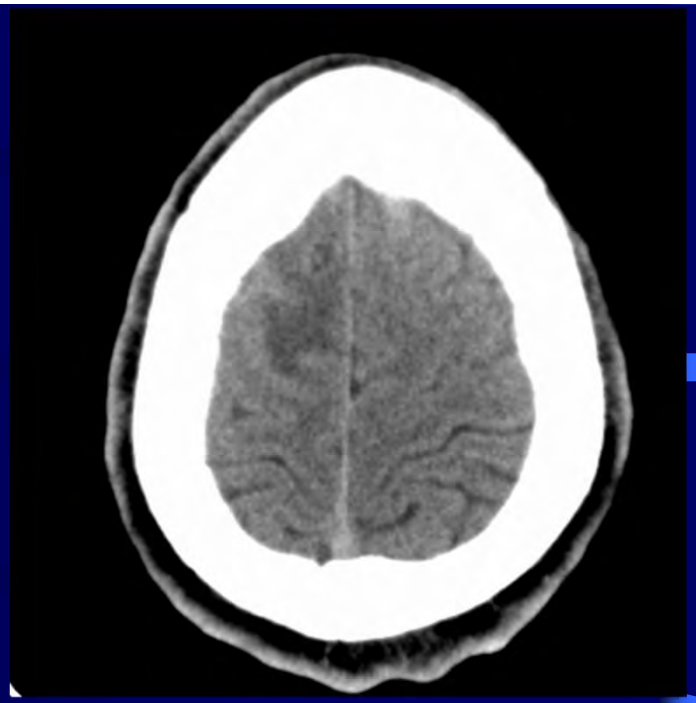

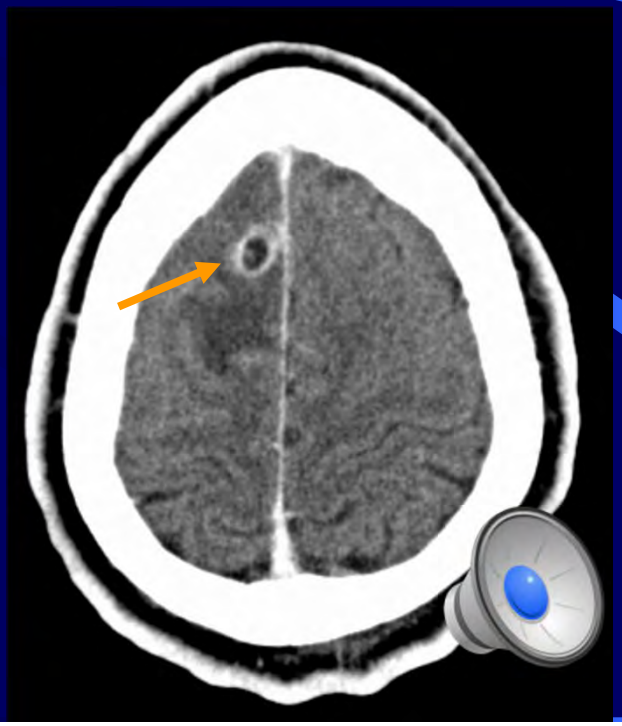

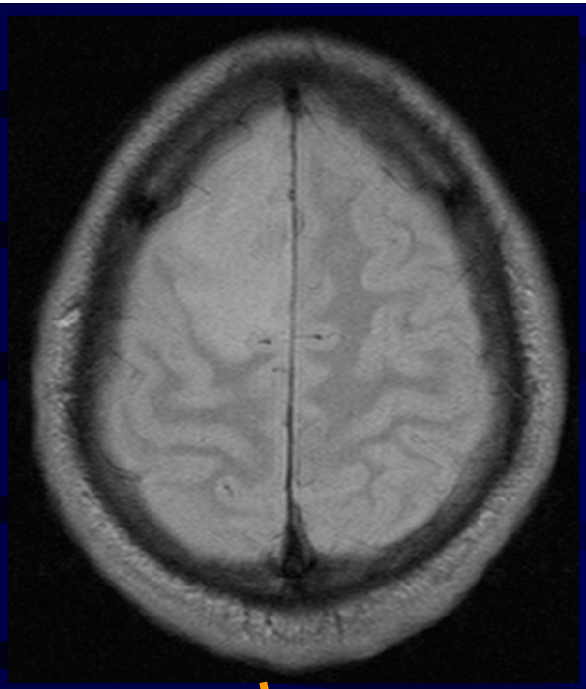

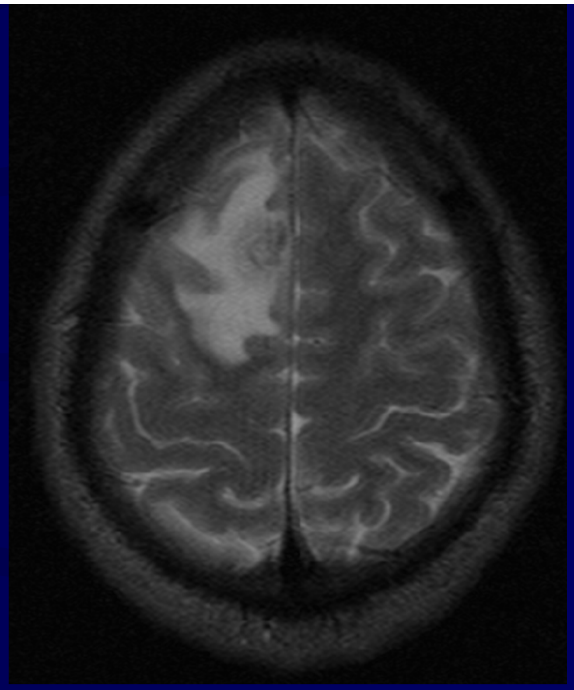

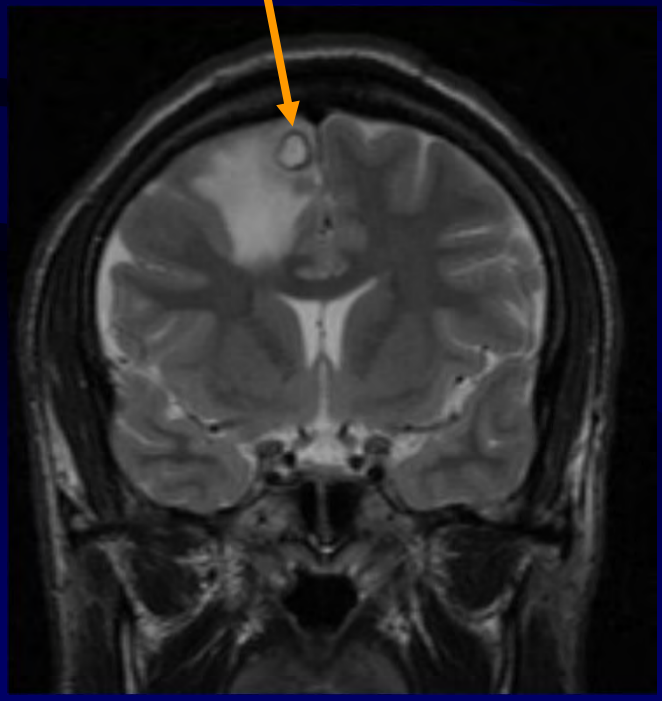

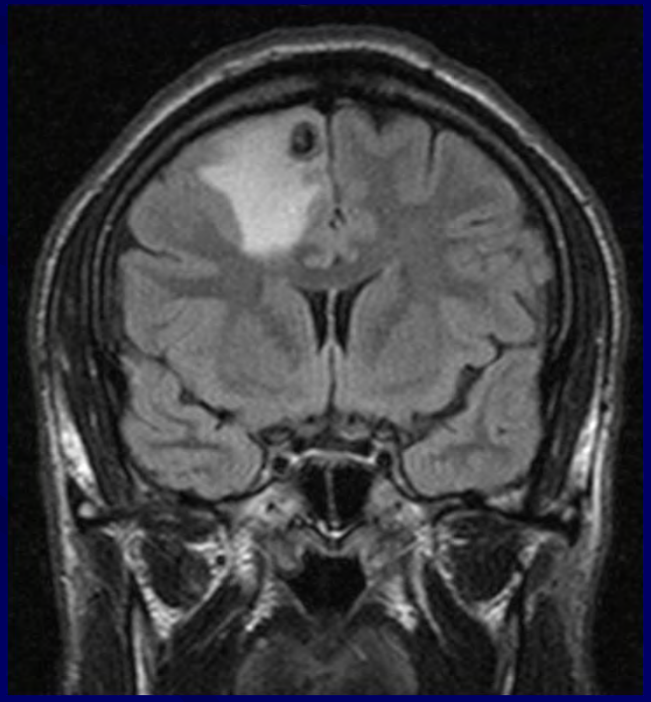

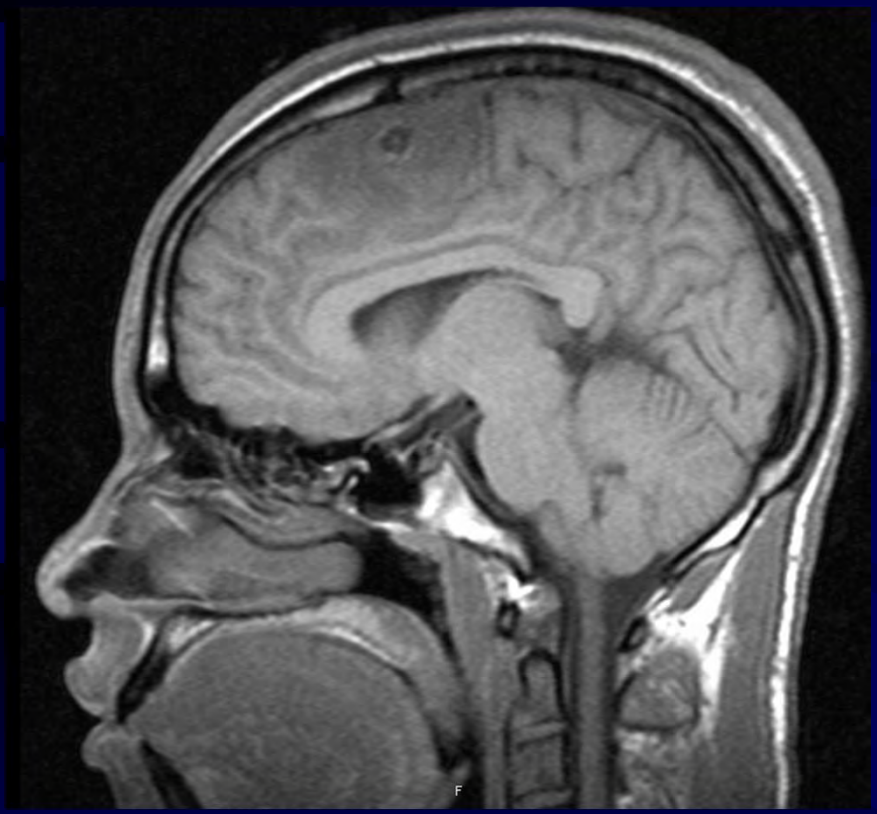

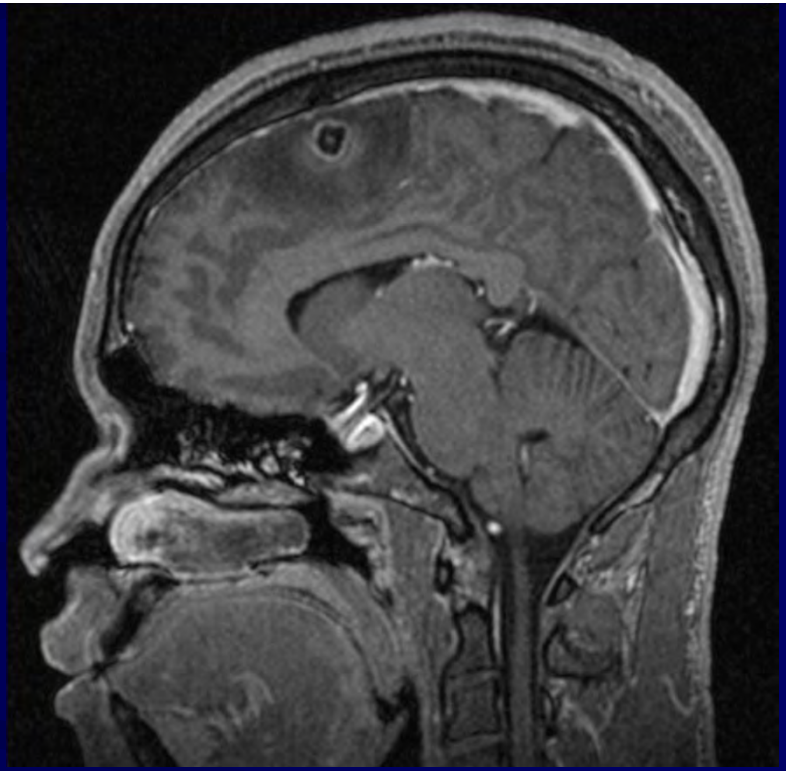

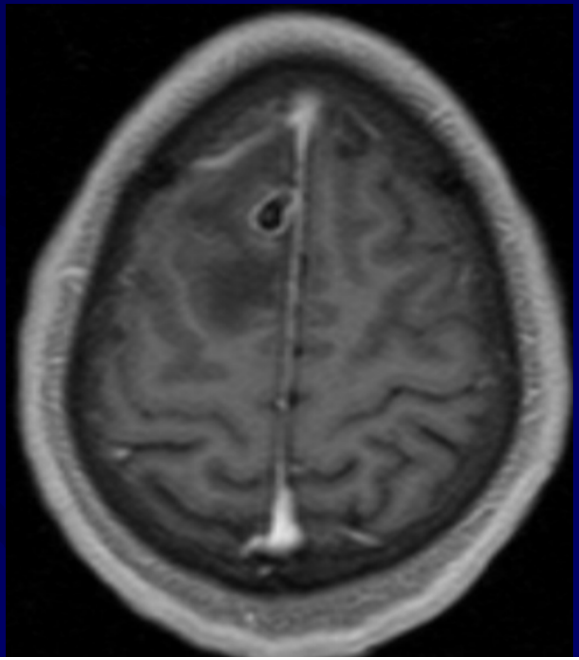

♀, 44 anos

Hemiparésia esquerda, de predomínio braquial

Tabagismo
Alcoolismo crónico

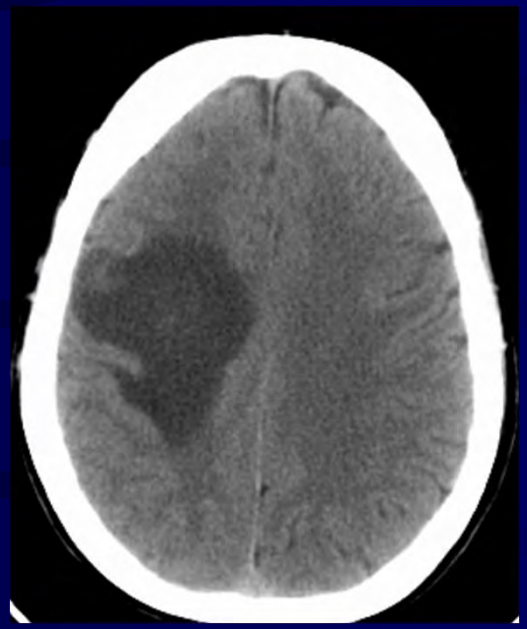

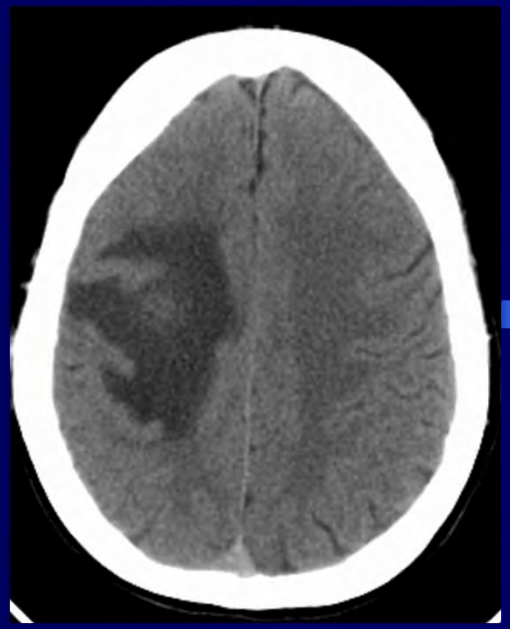

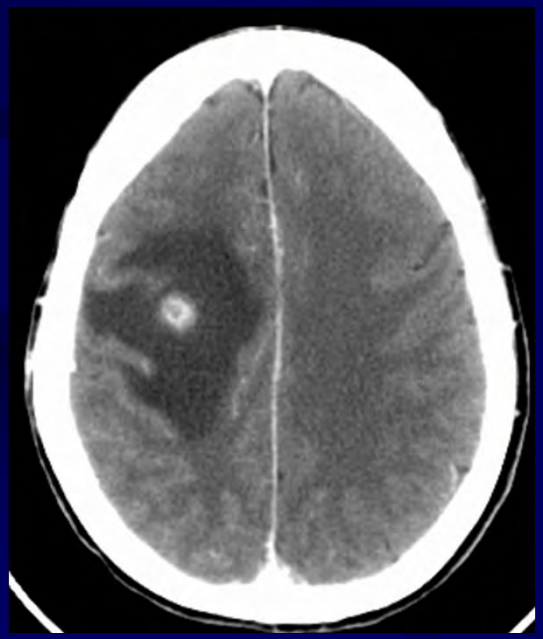

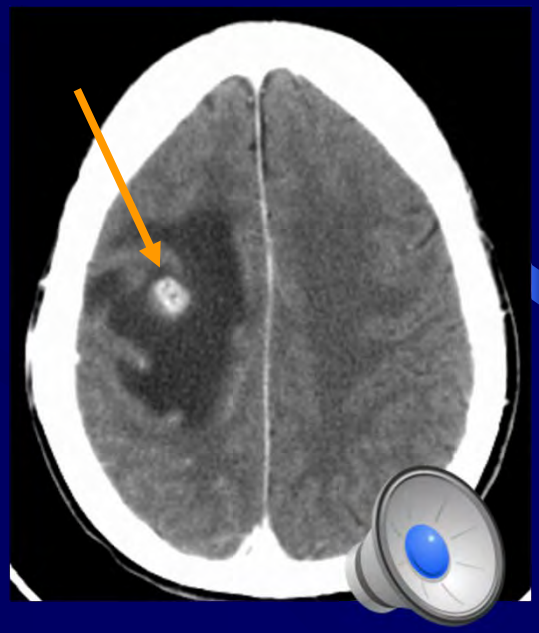

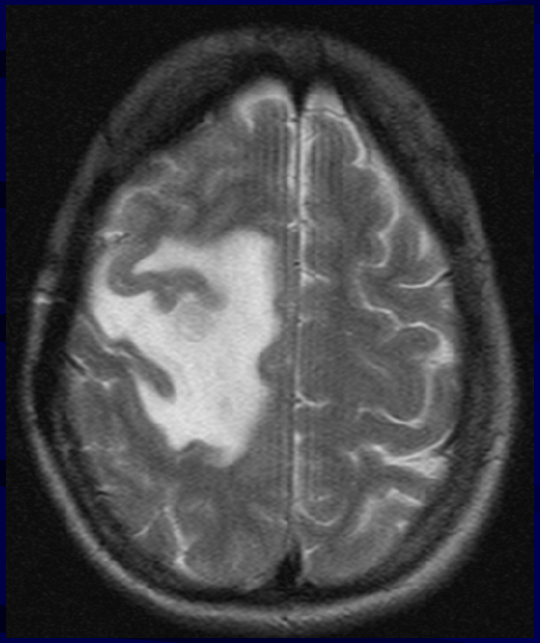

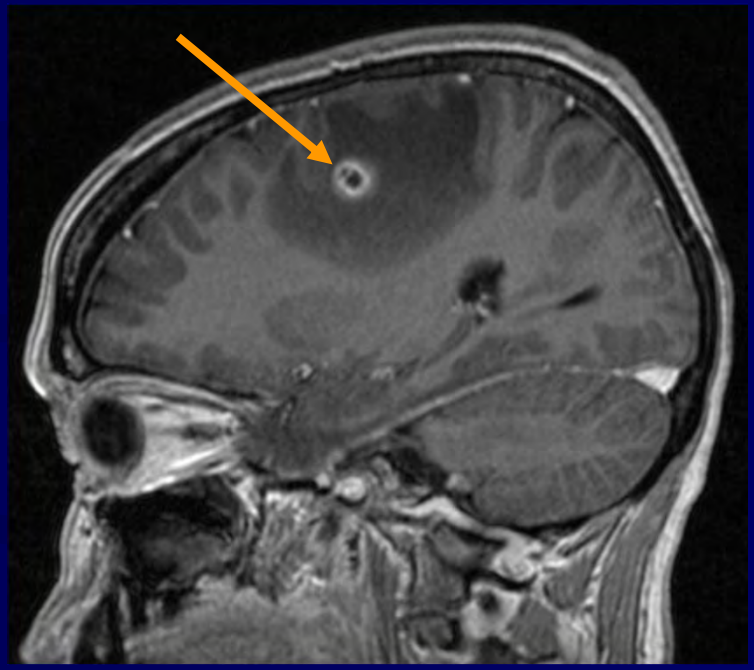

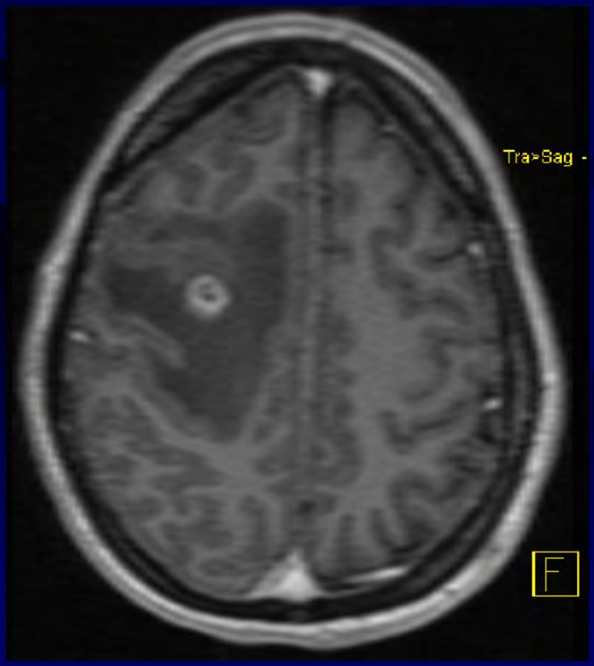
Tra>Sag -
F

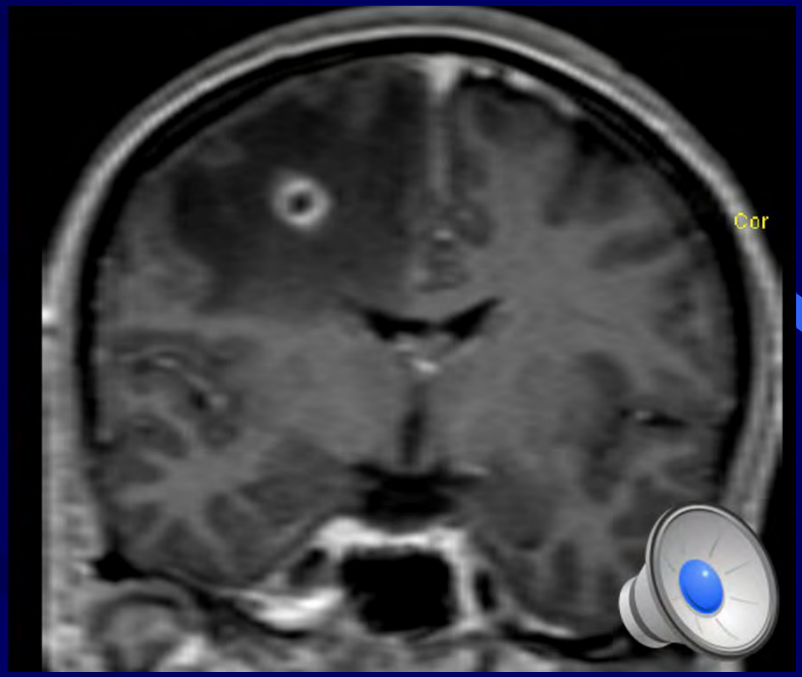
Cor

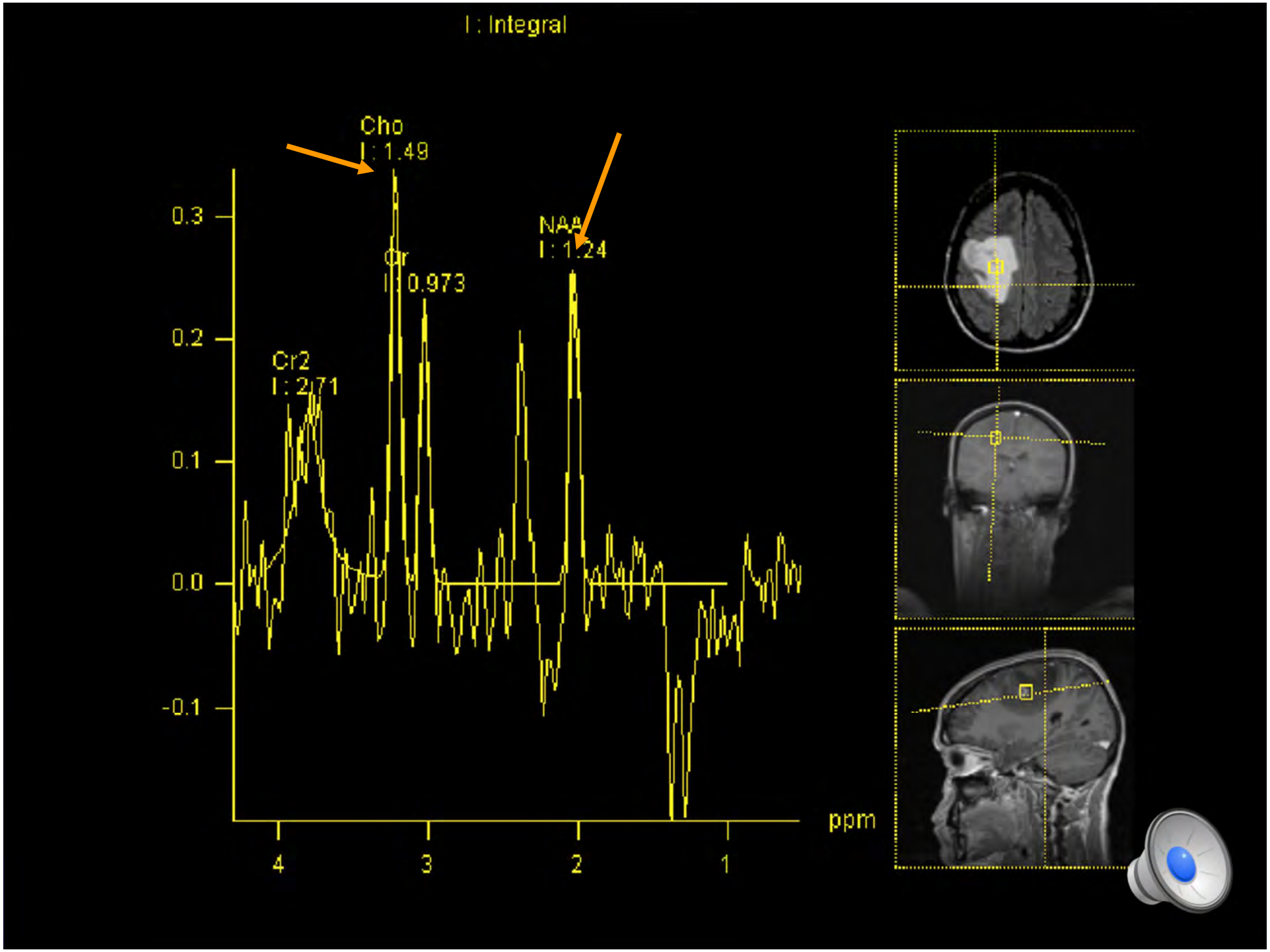
I : Integral
Cho
I : 1.49
Cr
I : 0.973
NAA
I : 1.24
Cr2
I : 2.71
0.3
0.2
0.1
0.0
-0.1
4
3
2
1
ppm

Lombalgias
Febre
Pós-cirurgia

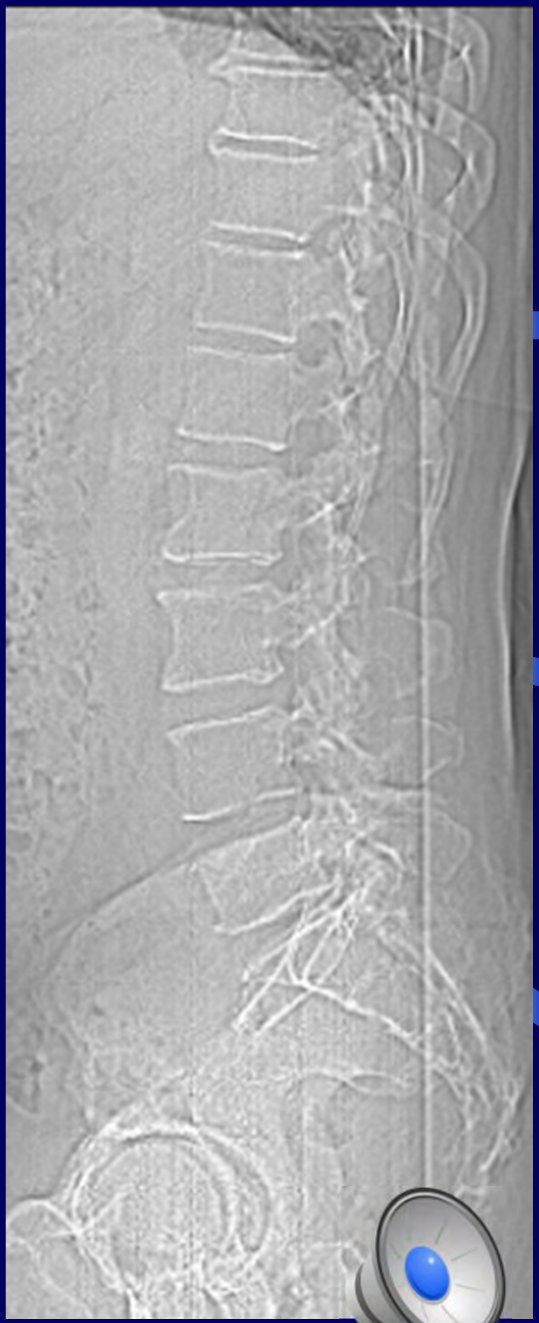

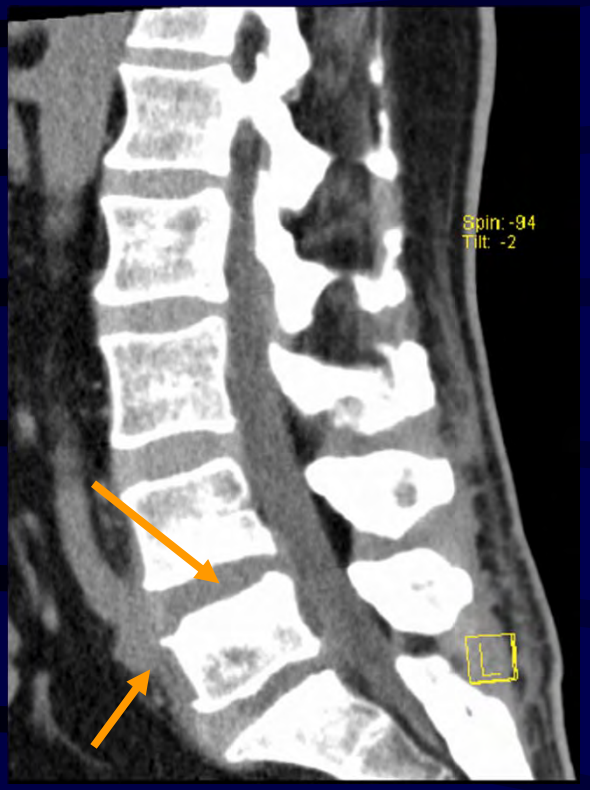
Spin: -94
Tilt: -2
L

Spin
Tilt:
L

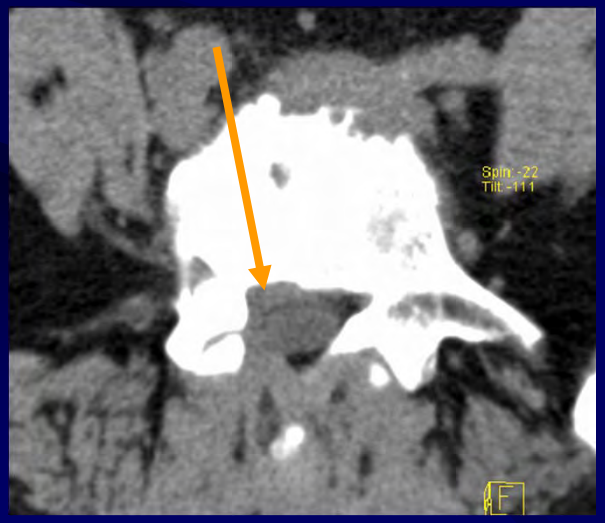
Spin: -22
Tilt: -111
F

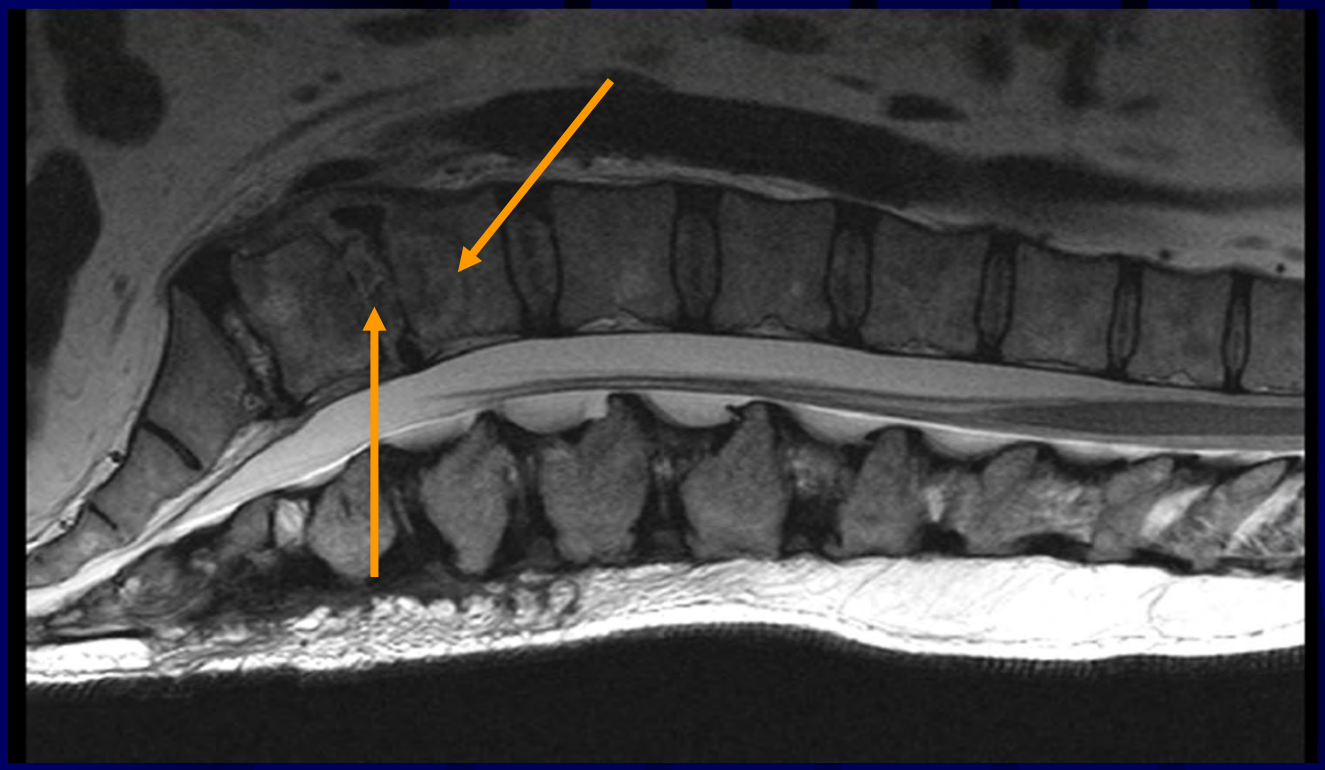

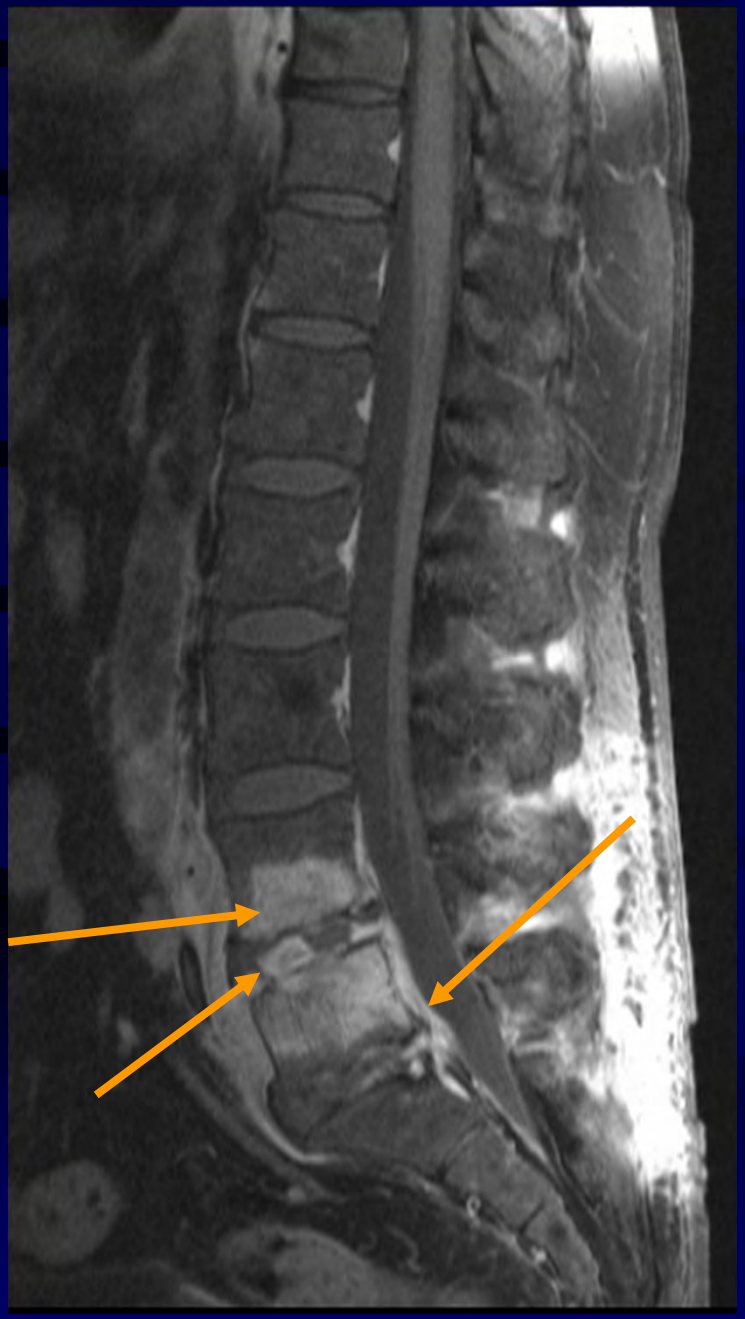

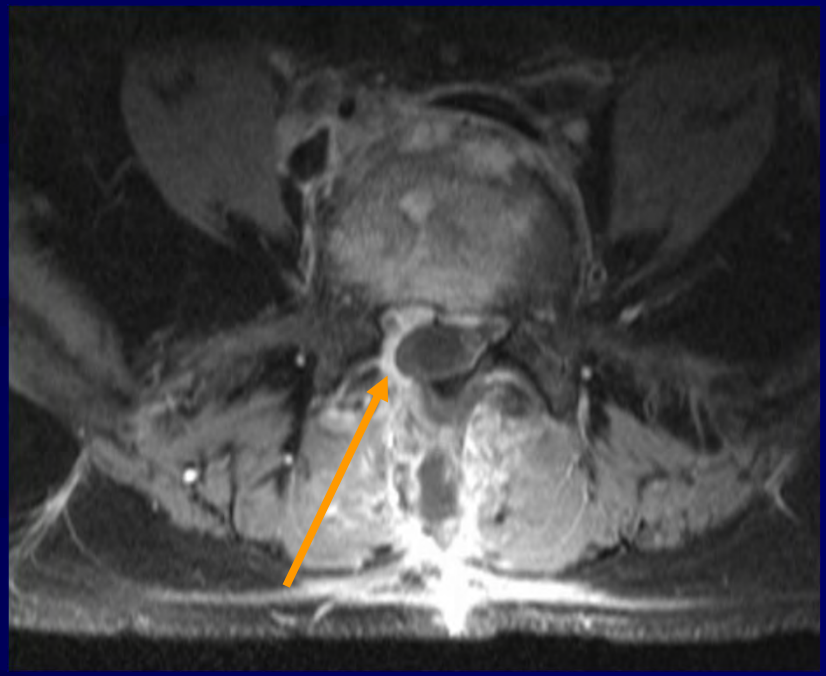

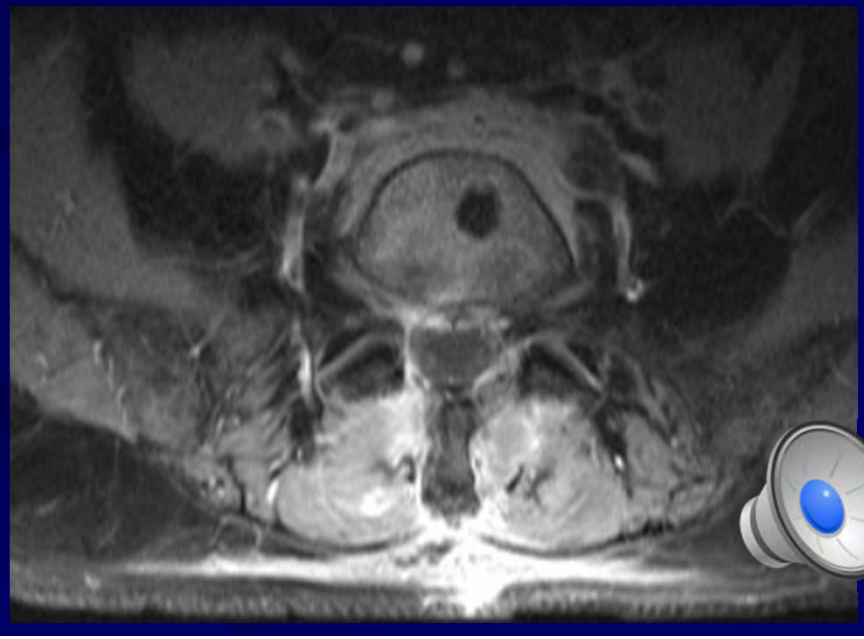

Tractografia

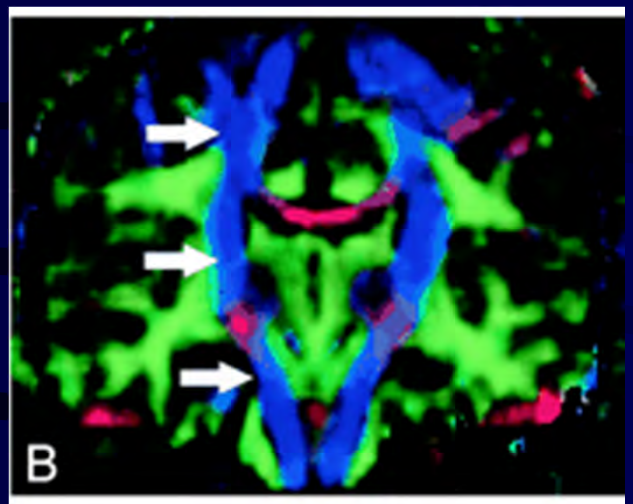

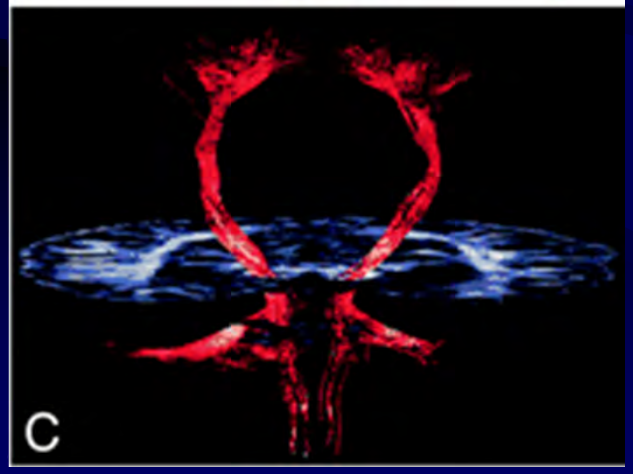

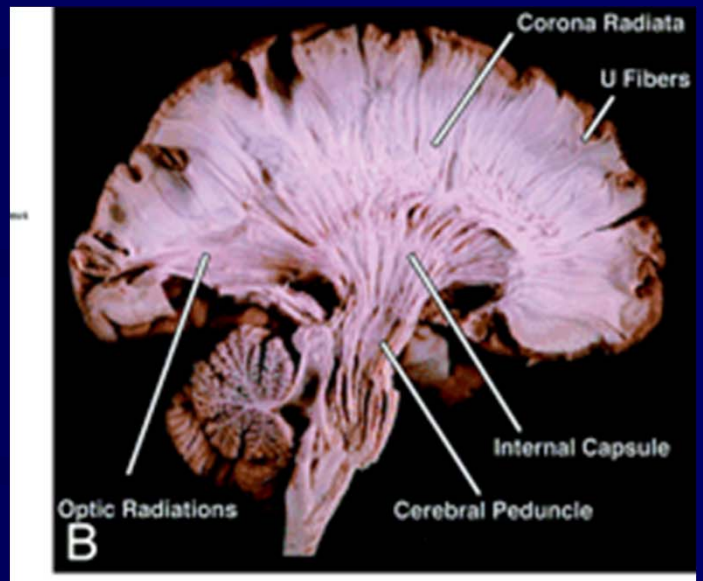

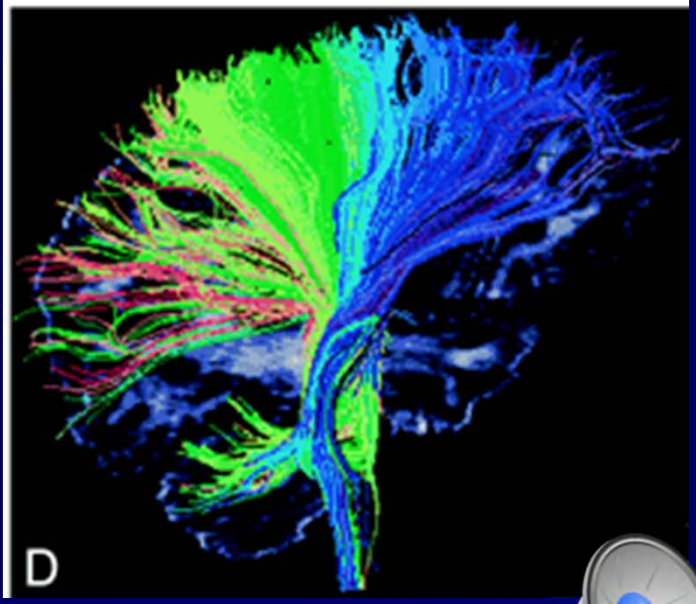

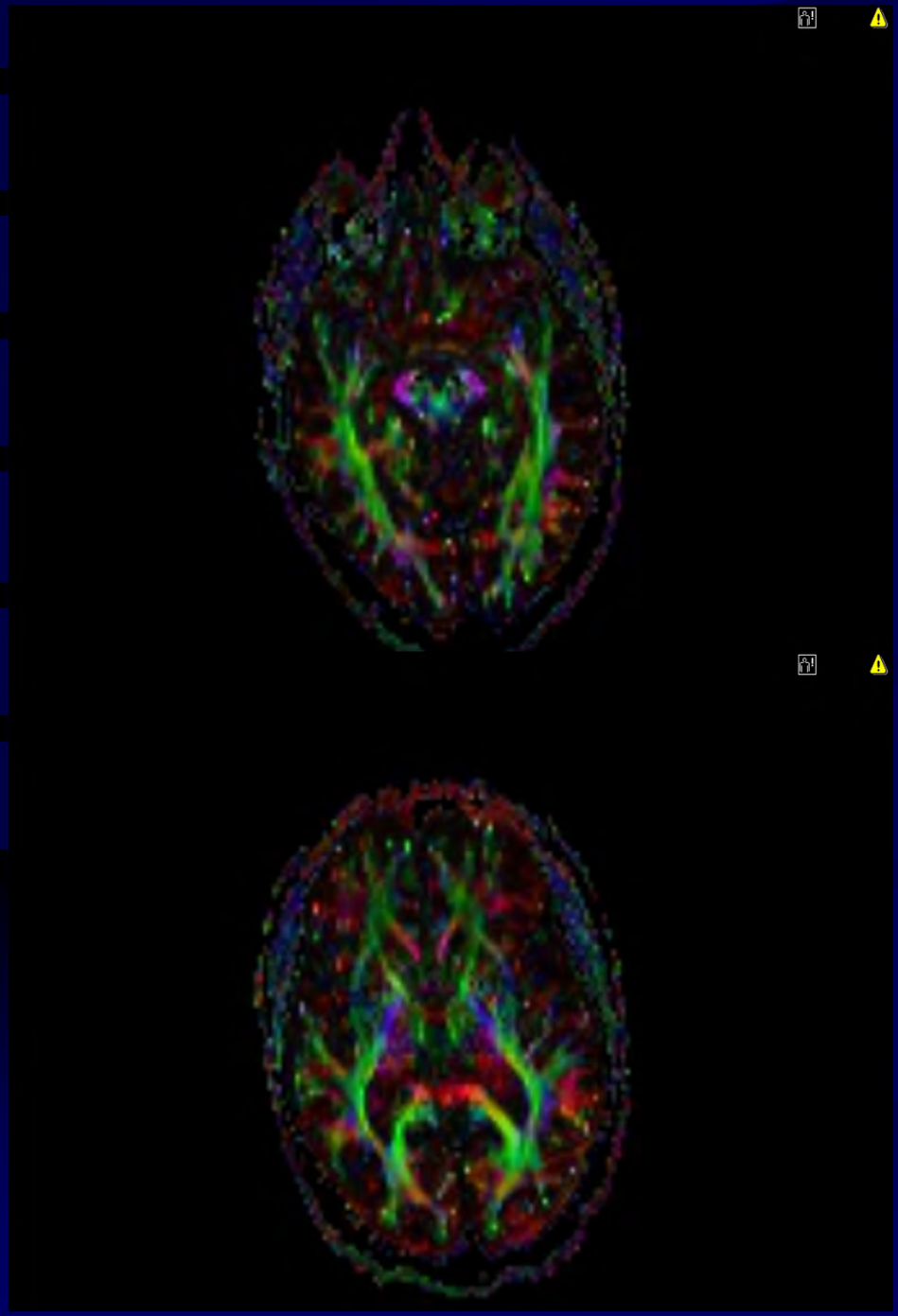

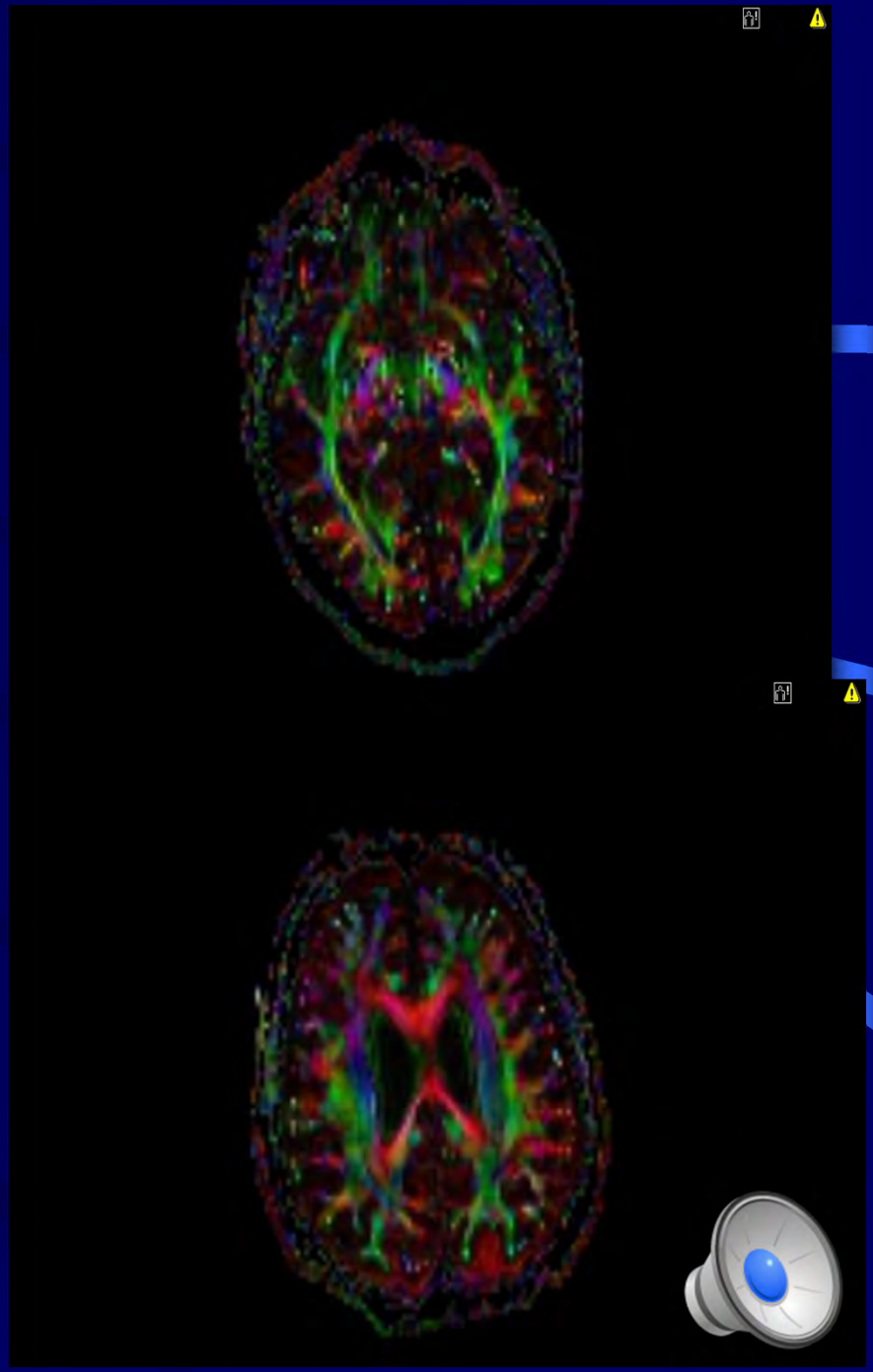

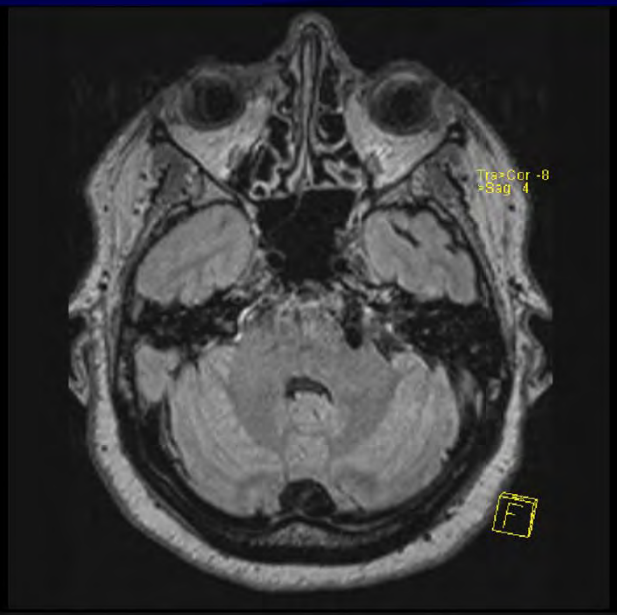
Tra>Cor -8
>Sag 4
F

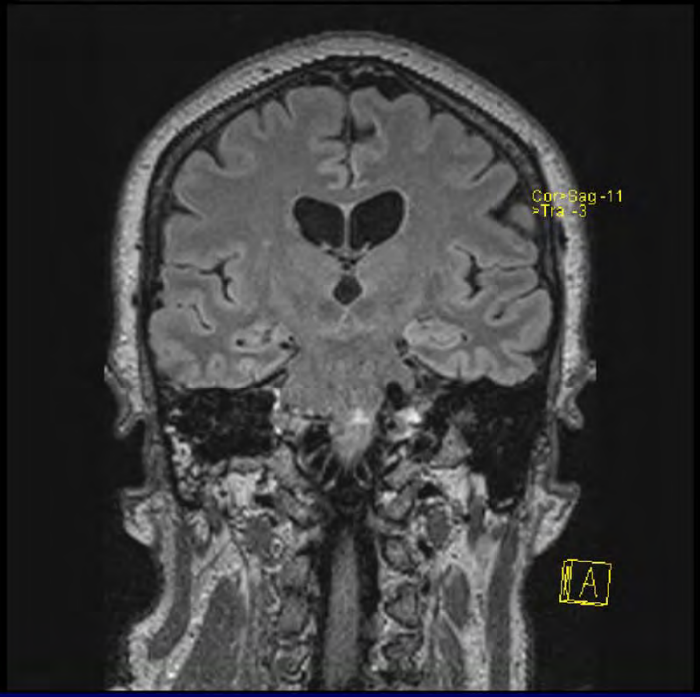
Cor>Sag -11
>Tra -3
A

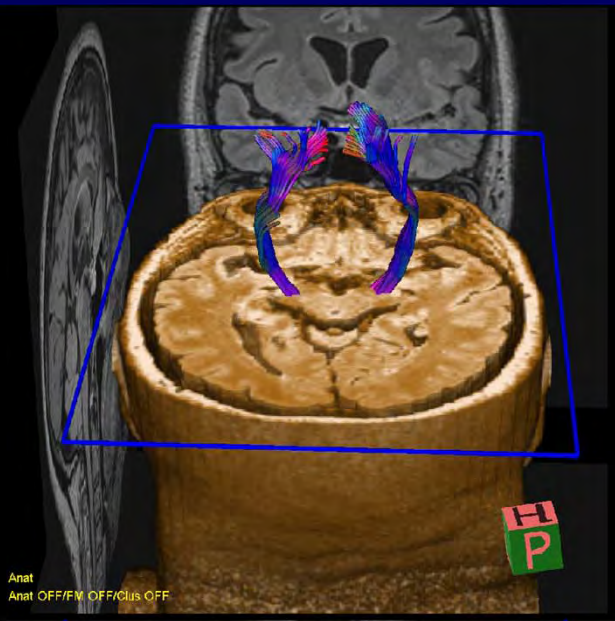
Anat
Anat OFF/FM OFF/Clus OFF
H
P

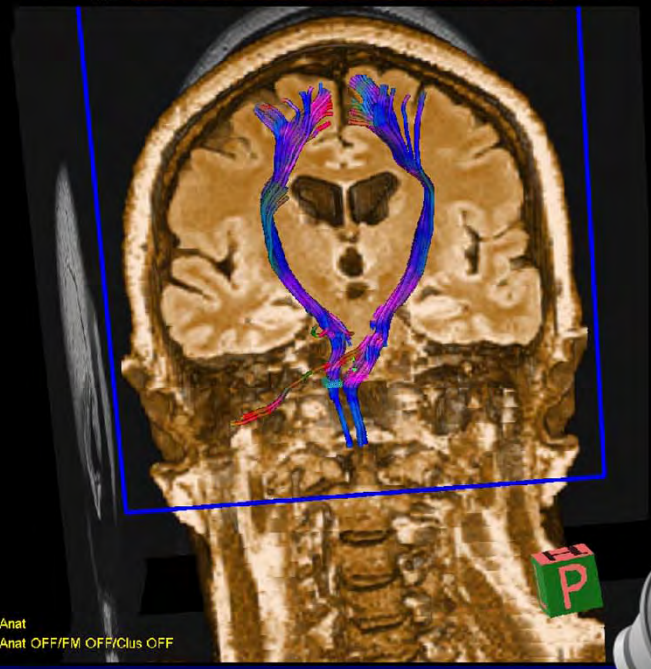
Anat
Anat OFF/FM OFF/Clus OFF
H
P

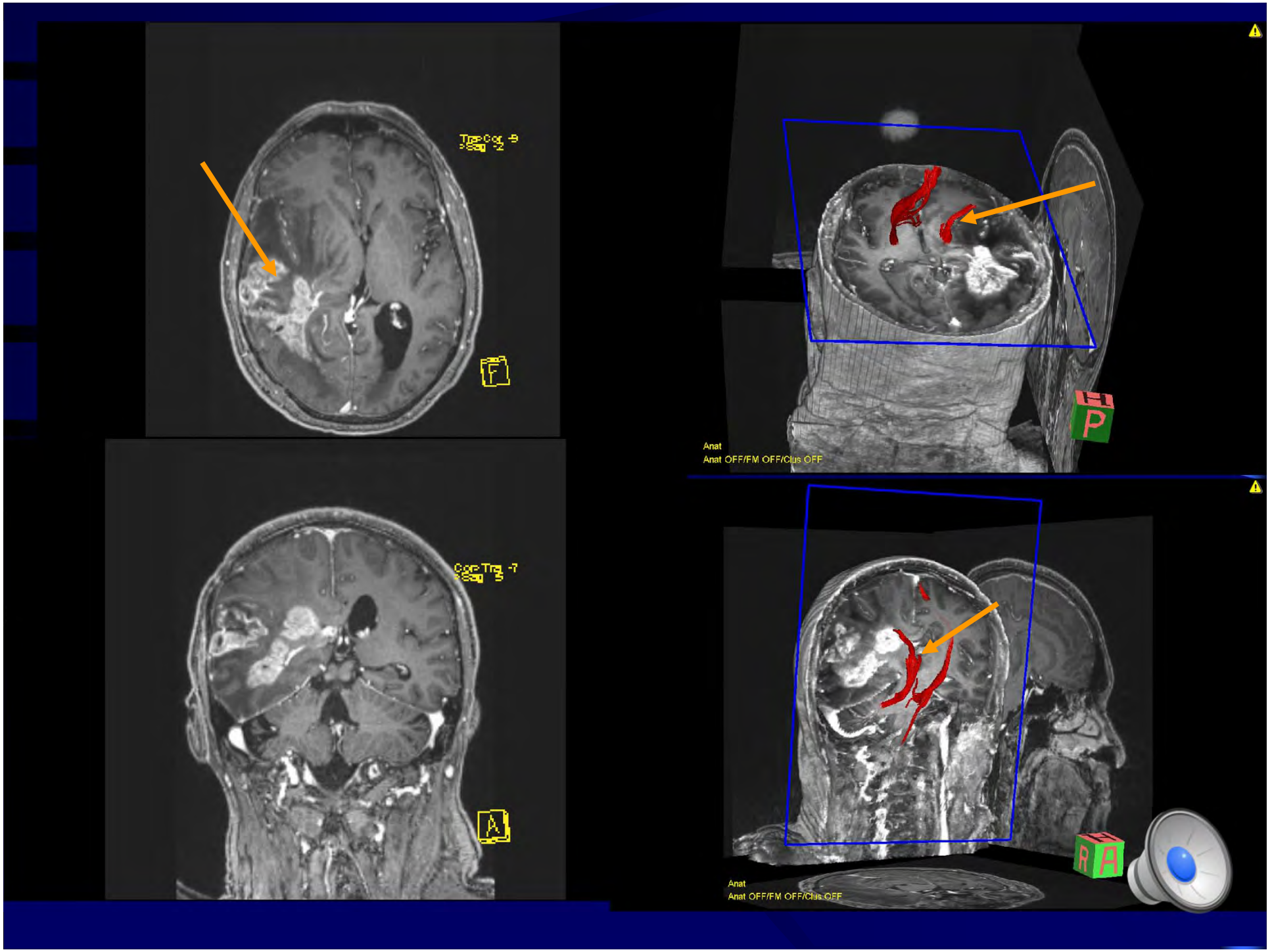
F
A
P
Anat
Anat OFF/FM OFF/Clus OFF
R
A
Anat
Anat OFF/FM OFF/Clus OFF

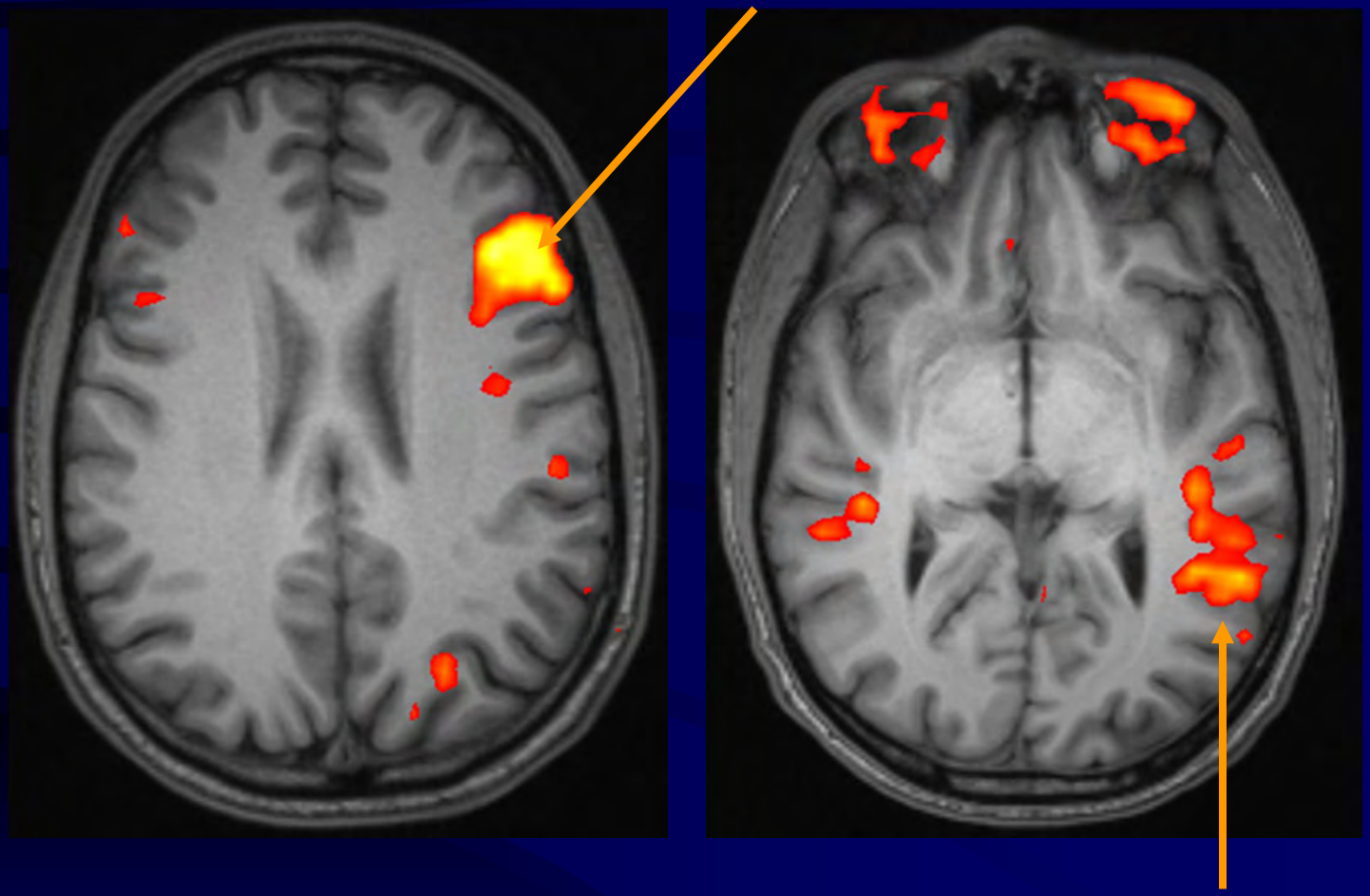

RM funcional da linguagem

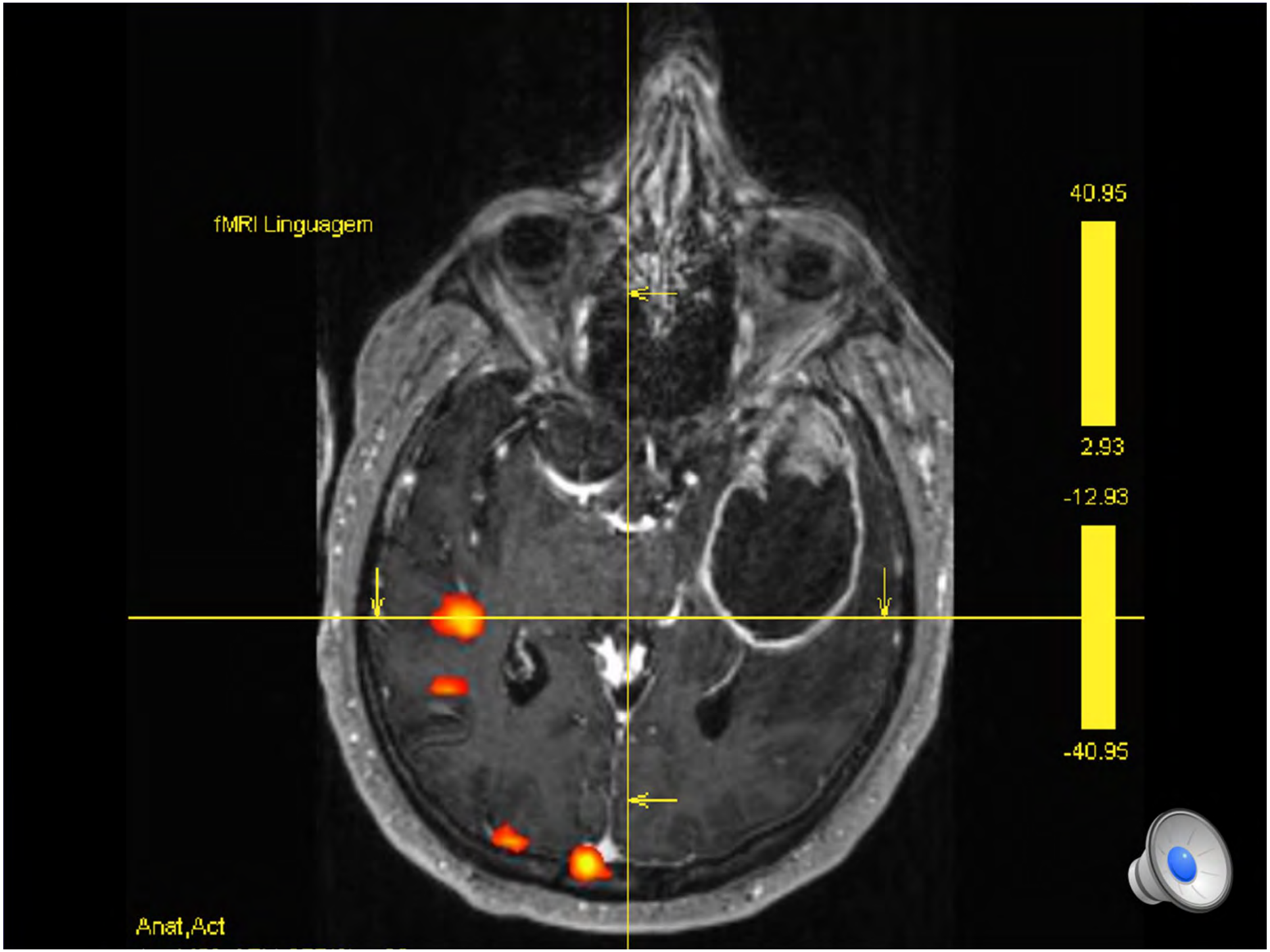
fMRI Linguagem
40.95
2.93
-12.93
-40.95
Anat,Act

http://www.neuroradiologyportal.com/index.html

http://spinwarp.ucsd.edu/NeuroWeb/TF.html

http://www.uhrad.com/mriarc.htm